

CASE REPORT

Myocarditis after COVID-19 mRNA vaccines

T. Koizumi, T. Awaya, K. Yoshioka, S. Kitano, H. Hayama, K. Amemiya, Y. Enomoto, Y. Yazaki, M. Moroi and M. Nakamura

From the Department of Cardiovascular Medicine, Toho University Ohashi Medical Center, 2-22-36 Ohashi, Meguro-ku, Tokyo 153-8515, Japan

Address correspondence to Dr T. Awaya, Department of Cardiovascular Medicine, Toho University Ohashi Medical Center, 2-22-36 Ohashi, Meguro-ku, Tokyo 153-8515, Japan. email: toru0228@gmail.com

Learning points for clinicians

To learn the diagnostic process for myocarditis in two patients in their twenties who had chest pain within 3 days after the second vaccination for COVID-19 through the interpretation of serial electrocardiography, strain analysis of cardiac echocardiogram and cardiac magnetic resonance imaging with late gadolinium enhancement and T1 mapping.

Case presentations

Patient 1

A 22-year-old man was admitted to our hospital with worsening chest pain 2 days after his second dose of the messenger RNA (mRNA)-1273 COVID-19 vaccine (Moderna). Although his transthoracic echocardiogram (TTE) showed no remarkable findings, the electrocardiogram (ECG) showed ST elevation in leads II, III, aVF and V3–6 (Figure 1a). Blood testing revealed elevated creatine kinase (CK) (758 IU/l), CK-MB (81.6 IU/l) and high-sensitivity troponin T (hsTnT) (0.906 ng/ml). Emergency coronary angiography (CAG) revealed no coronary artery stenosis. Endomyocardial biopsy showed no inflammatory cell infiltration. Antibody titres of various viruses, including SARS-CoV-2, were negative, and COVID-19 vaccine-associated myocarditis was suspected. He did not develop any life-threatening arrhythmias and his symptoms were resolved within a few days with non-steroidal anti-inflammatory drug (NSAID) administration (ibuprofen 600 mg/day). He was discharged on the fourth day.

Patient 2

A 27-year-old man was transferred to the emergency room with worsening chest pain 3 days after his second dose of the mRNA-1273 COVID-19 vaccine (Moderna). His ECG on admission showed slightly ST elevation in leads II, III and aVF (Figure 1b), and TTE showed no specific findings. His serum CK (241 IU/l), CK-MB (23.2 IU/l) and hsTnT (0.290 ng/ml) levels were slightly elevated. Emergency CAG revealed no coronary artery lesions, and an endomyocardial biopsy showed no remarkable findings. His symptoms resolved with a few days of sufficient rest and NSAID administration (ibuprofen 600 mg/day). We performed cardiac magnetic resonance imaging (MRI) and strain analysis for the diagnosis on the fourth day. Cardiac MRI demonstrated late gadolinium enhancement (LGE) in the epicardial to the mid-wall in the left ventricle inferolateral wall (Figure 2a). T1 map and extracellular volume (ECV) map showed elevated native T1 values and ECV in the regions with LGE (Figure 2b and c). Consistent with cardiac MRI findings, the values of peak systolic longitudinal strain in the inferolateral segments of epicardial to mid-layer (Figure 2d and e) were lower than those in the endocardial layer (Figure 2f) when measured by speckle-tracking echocardiography, which strongly suggested myocardial injury by acute myocarditis. Viral antibody titres, including for SARS-CoV-2, were negative, and COVID-19 mRNA vaccine-associated myocarditis was presumed due to the strong chronological association.

Discussion

The ECG of Patient 1 showed a typical change for myocarditis (Figure 1a) and the diagnosis of myocarditis was easy. However, the ECG of Patient 2 did not show a typical change (Figure 1b), and there was no abnormality of wall motion on TTE. Therefore, cardiac

Submitted: 9 September 2021; Revised (in revised form): 15 September 2021

© The Author(s) 2021. Published by Oxford University Press on behalf of the Association of Physicians. All rights reserved.

For permissions, please email: journals.permissions@oup.com

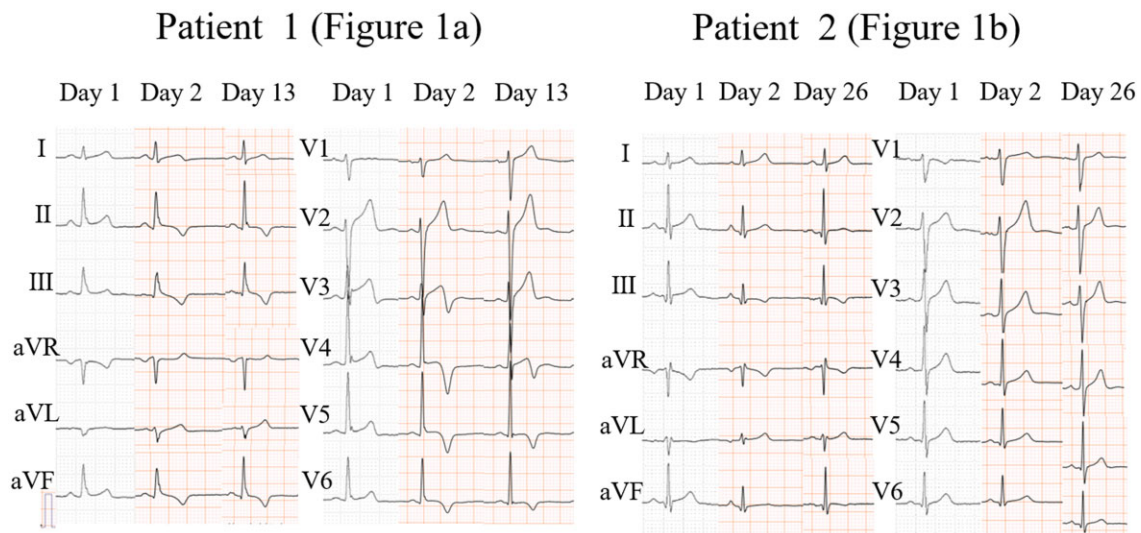


Figure 1. (a) An electrocardiogram (ECG) showed ST elevation in leads II, III, aVF and V3–V6 on Day 1. On Day 2, ECG exhibited a negative T wave in leads II, III, aVF and V3–V6 and negative T wave normalized in V3 lead on Day 13. (b) An ECG showed a slightly ST-segments elevation in leads II, III and aVF on Day 1. Compared to Day 1, ECG exhibited low voltage in leads II, III, aVF and a negative T wave in leads III on Day 2. On Day 26, low voltage in II, III and aVF normalized.

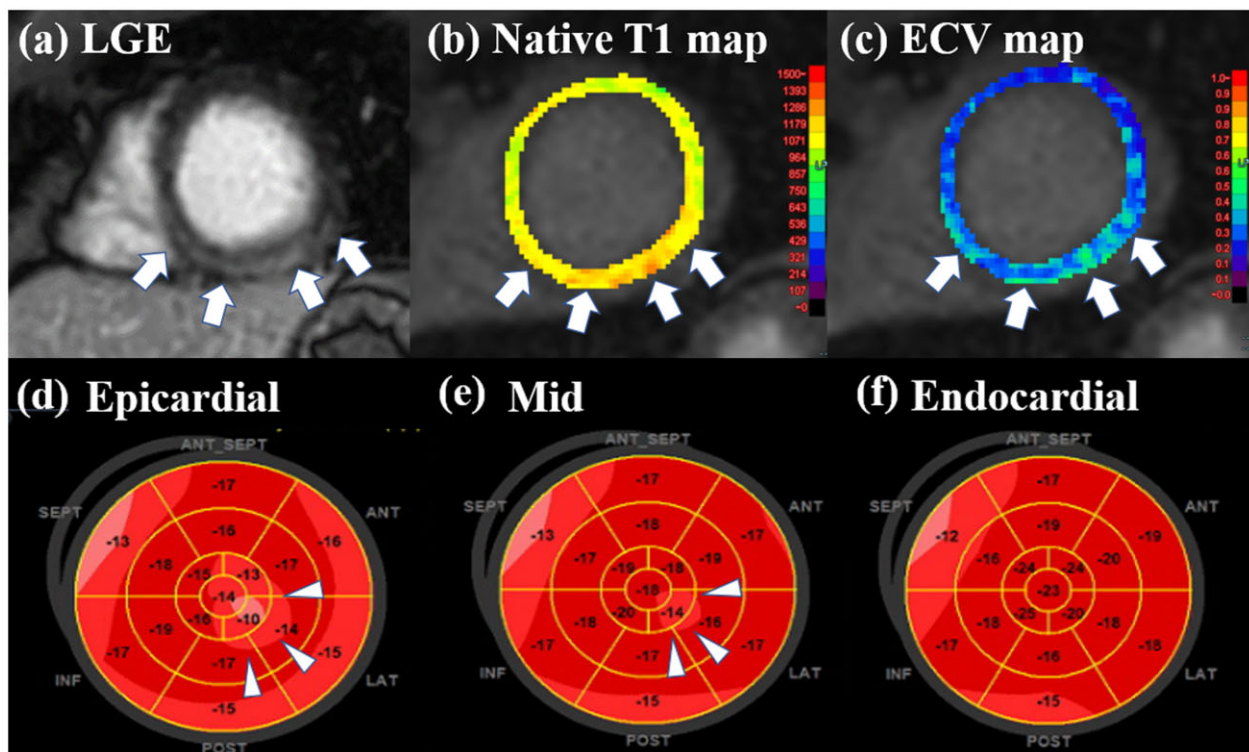


Figure 2. Cardiac magnetic resonance imaging (MRI) (short-axis view) demonstrated late gadolinium enhancement (LGE) in the epicardial to the mid-wall in the left ventricle inferolateral wall (arrows) (a), which are consistent with myocarditis. T1 map and extracellular volume (ECV) map showed elevated native T1 values and ECV in the regions with LGE (arrows) (b and c). Consistent with cardiac MRI findings, the values of peak systolic longitudinal strain in the inferolateral segments of epicardial (d) to the mid-layer (e) (arrowheads) were lower (–10% and –14%, respectively) than those in the endocardial layer (f) when measured by speckle-tracking echocardiography (EchoPAC Software GE Healthcare, Milwaukee, WI, USA) and left ventricular global longitudinal strain was –16.8%.

MRI, strain analysis (Figure 2) and serial ECG (Figure 1b) were useful for the diagnosis of myocarditis. The US Centres for Disease Control and Prevention have reported several cases of post-vaccination myocarditis, and the risk of myocarditis is estimated to be significantly higher among young males after their second dose of mRNA COVID-19 vaccines (aged ≥ 65 years: 1.4 cases per million vs. aged 12–17 years: 66.7 cases per million).¹ It is possible that

autoantibodies, such as aquaporin-4, are also produced during the production of antibodies against COVID-19 spike protein,² and an inflammatory infiltrate composed of T cells, macrophages, eosinophils and B cells has been reported in association with COVID-19 vaccination.³ Thus, post-vaccination myocarditis is also suggested to be associated with autoimmunity and allergies, whereas reports of herpes zoster after vaccination suggest that a temporary

decrease in cellular immunity.⁴ ECG, MRI and troponin could contribute to diagnoses of post-vaccination myocarditis.^{2,5} A recent study showed that global longitudinal strain values are useful for diagnosing myocarditis.⁶ Although the benefits of the vaccines outweigh the risks, we should be aware that myocarditis can occur after COVID-19 mRNA vaccination regardless of race, especially in young males.

Conflict of interest. None declared.

References

1. Bozkurt B, Kamat I, Hotez PJ. Myocarditis with COVID-19 mRNA vaccines. *Circulation* 2021; **144**:471–84.
2. Muthukumar A, Narasimhan M, Li QZ, Mahimainathan L, Hitto I, Fuda F, et al. In-depth evaluation of a case of presumed myocarditis after the second dose of COVID-19 mRNA vaccine. *Circulation* 2021; **144**:487–98.
3. Verma AK, Lavine KJ, Lin CY. Myocarditis after Covid-19 mRNA vaccination. *N Engl J Med* 2021 Aug 18;NEJMc2109975.
4. Chiu HH, Wei KC, Chen A, Wang WH. Herpes zoster following COVID-19 vaccine: report of 3 cases. *QJM* 2021 Jul 22;hcab208 (Epub ahead of print).
5. Sulemankhil I, Abdelrahman M, Negi SI. Temporal association between the COVID-19 Ad26.COV2.S vaccine and acute myocarditis: a case report and literature review. *Cardiovasc Revasc Med* 2021 Aug 16:S1553-8389(21)00578-9 (Epub ahead of print).
6. Farzaneh-Far A, Romano S. Imaging and impact of myocardial strain in myocarditis. *JACC Cardiovasc Imaging* 2020; **13**:1902–5.