



Since January 2020 Elsevier has created a COVID-19 resource centre with free information in English and Mandarin on the novel coronavirus COVID-19. The COVID-19 resource centre is hosted on Elsevier Connect, the company's public news and information website.

Elsevier hereby grants permission to make all its COVID-19-related research that is available on the COVID-19 resource centre - including this research content - immediately available in PubMed Central and other publicly funded repositories, such as the WHO COVID database with rights for unrestricted research re-use and analyses in any form or by any means with acknowledgement of the original source. These permissions are granted for free by Elsevier for as long as the COVID-19 resource centre remains active.

Clinical Communications: Adult

Cardiac Tamponade After COVID-19 Vaccination

Adam T. Hryniewicki, Vaishal M. Tolia, and Rahul V. Nene

Department of Emergency Medicine, University of California San Diego, San Diego, California

Reprint Address: Rahul V. Nene, MD, PhD, Department of Emergency Medicine, UC San Diego School of Medicine, 200 W. Arbor Dr. #8676, San Diego, CA 92103

Abstract—Background: Acute pericarditis is a diffuse inflammation of the pericardial sac with many well-defined etiologies. Acute pericarditis as a vaccine-related adverse event is a rare entity, and the association between pericarditis and the immunogenic response to Coronavirus disease 2019 (COVID-19) vaccines is still being fully characterized. **Case Report:** A previously healthy 18-year-old man presented with fever, pleuritic chest pain, and shortness of breath 3 weeks after receiving the first dose of a COVID-19 mRNA-based vaccine. The patient was found to have a large pericardial effusion with early tamponade physiology requiring pericardiocentesis. **Why Should an Emergency Physician Be Aware of This?:** As COVID-19 vaccination becomes more prevalent globally, physicians should be aware of pericarditis as a rare but potentially serious adverse reaction. Although a direct causal link cannot be demonstrated, we present this case to increase awareness among emergency physicians of pericarditis as a rare, but potentially serious adverse event associated with COVID-19 vaccination. Published by Elsevier Inc. This is an open access article under the CC BY-NC-ND license (<http://creativecommons.org/licenses/by-nc-nd/4.0/>)

Keywords—pericarditis; COVID-19 vaccine; vaccine-related adverse event

Introduction

Since April 2021, the Centers for Disease Control and Prevention (CDC) has seen an increase in reports of pericarditis and myocarditis after vaccination with the

mRNA-based vaccines from Pfizer-BioNTech (Pfizer, New York, NY; BioNTech, Mainz, Germany) and Moderna (Cambridge, MA), particularly in adolescents and young adults. Acute pericarditis is a diffuse inflammation of the pericardial sac with many well-defined etiologies. Acute pericarditis as a vaccine-related adverse event is a rare entity, and the association between pericarditis and the immunogenic response to Coronavirus disease 2019 (COVID-19) vaccines is still being fully characterized. Here, we present a case of a previously healthy 18-year-old man who presented with fever and pleuritic chest pain after receiving the first dose of a COVID-19 mRNA-based vaccine. The patient was found to have acute pericarditis and developed a large pericardial effusion with early tamponade physiology and required emergent pericardiocentesis.

Case Report

A previously healthy 18-year-old man presented with a chief complaint of fever, pleuritic chest pain, and shortness of breath 3 weeks after receiving the first dose of the Pfizer-BioNTech COVID-19 vaccine. On arrival to the Emergency Department (ED), vital signs were remarkable for a temperature of 37.94°C (100.3°F) and heart rate of 111 beats/min. The patient had an unremarkable physical examination other than regular tachycardia. Electrocardiogram (ECG) demonstrated diffuse ST elevations and PR depressions ([Figure 1](#)), concerning for acute peri-

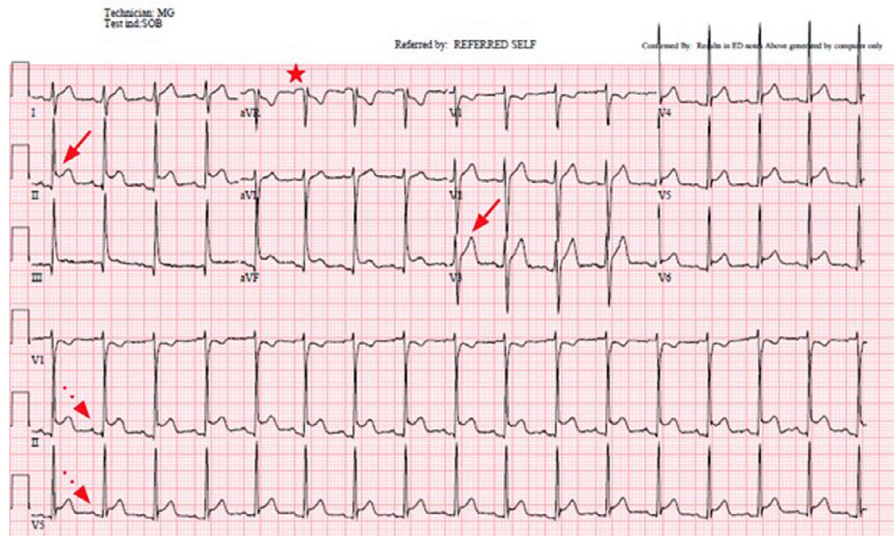


Figure 1. Electrocardiogram from initial presentation demonstrating diffuse ST elevations (solid arrows), PR depressions (dotted arrows), and PR elevation in aVR (star), concerning for acute pericarditis.

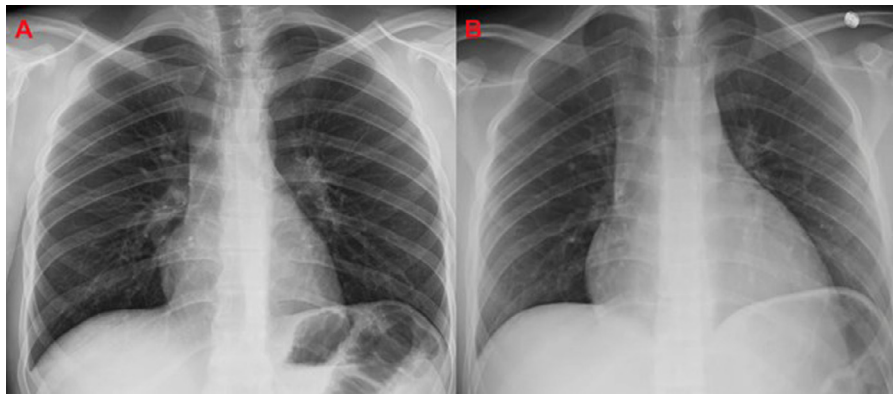

Figure 2. Chest radiographs on (A) initial presentation (within normal limits), and (B) on return visit 2 weeks later now demonstrating enlarged cardiac silhouette, consistent with large pericardial effusion.

carditis. Chest x-ray study, formal echocardiogram, and troponins were all within normal limits. After discussion with the Cardiology service, he was discharged on a regimen of ibuprofen 800 mg every 8 h, with a plan to follow-up with Cardiology as an outpatient. Three days later, his chest pain was persistent, and he was started on additional colchicine 0.6 mg daily.

Approximately 10 days later, the patient returned to the ED with ongoing fever, pleuritic chest pain, shortness of breath, and dizziness. Vital signs were remarkable for an elevated temperature to 37.83°C (100.1°F), tachycardia to 120 beats/min, and tachypnea to 31 breaths/min. Blood pressure was normal. ECG demonstrated persistent diffuse ST elevations. Chest x-ray study now showed an enlarged cardiac silhouette (Figure 2). Echocardiogram demonstrated a large pericardial effusion with evidence

of early tamponade, including a dilated inferior vena cava and right atrial diastolic collapse (Figure 3). The patient was admitted to the cardiac intensive care unit and underwent emergent pericardiocentesis with removal of approximately 600 mL of serosanguinous fluid. Pericardial fluid studies were consistent with an exudative process. The patient was discharged 4 days later on indomethacin 25 mg every 6 h and colchicine 0.6 mg every 12 h. He was readmitted to the hospital 1 week later for persistent tachycardia and recurrent pericardial effusion, which improved after intravenous ketorolac and intravenous methylprednisolone. He was ultimately discharged on prednisone 40 mg daily, celecoxib 200 mg every 12 h, and a plan to start rilonacept, an interleukin-1 inhibitor recently approved for the treatment of recurrent pericarditis (1).

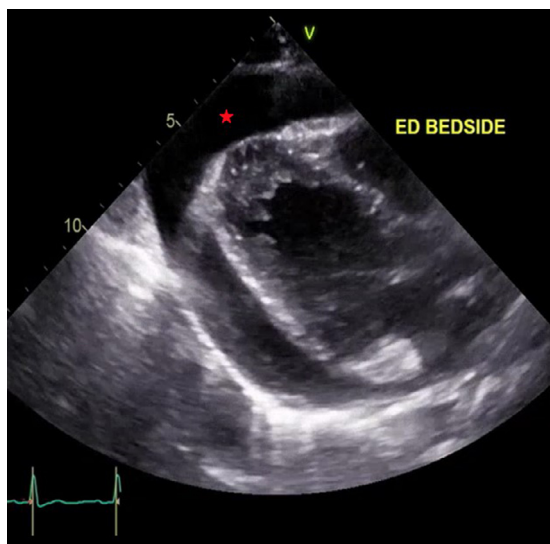


Figure 3. Echocardiogram demonstrating large pericardial effusion (star).

Discussion

Beginning in April 2021, there has been increasing awareness of COVID-19 vaccine-associated adverse reactions, particularly pericarditis and myocarditis in younger patients. Here, we present a case of pericarditis 3 weeks after mRNA-based vaccination, which demonstrated a classic constellation of symptoms including pleuritic chest pain, ECG abnormalities, history of fever, and a pericardial effusion. ECG abnormalities of pericarditis typically include diffuse concave ST elevations and PR depressions in the precordial and limb leads (I, II, III, aVL, aVF, V2-6) with reciprocal ST depression and PR elevation in aVR and lead I (2,3).

The various etiologies of pericarditis can be categorized into infectious (primarily viral), non-infectious (e.g., neoplasm, trauma, metabolic), and inflammatory (e.g., immunologic, rheumatologic), though up to 86% may be idiopathic (4,5). Pericardial effusions may be present in up to two-thirds of pericarditis cases, although large effusions (> 20 mm in width) are much more rare and constitute only 3% of cases (6). Echocardiography is necessary for patients with suspected or confirmed pericarditis, as a pericardial effusion can progress to tamponade physiology prior to enlarging the cardiac silhouette on chest x-ray study or prior to the patient developing significant vital sign abnormalities.

Nonsteroidal anti-inflammatory drugs remain the cornerstone of treatment (ibuprofen 600–800 mg every 6 to 8 h), and colchicine has been shown to reduce symptoms at 72 h and the risk of recurrent pericarditis (7,8). Patients with large pericardial effusions, and clearly those

with tamponade physiology, require pericardiocentesis and placement of a pericardial drain.

Pericarditis is a rare event after immunizations, however, it has been described after vaccinations for influenza and smallpox (9,10). One study determined that the rate of inflammatory cardiac conditions—myocarditis, pericarditis, and dysrhythmias—after immunization with live virus vaccines (excluding smallpox) was no greater than the background rate (11). However, the incidence of myopericarditis after immunization with novel vaccine technologies, namely the mRNA vaccines widely adopted for the COVID-19 pandemic, has yet to be fully elucidated. A recent case series reported seven cases of myopericarditis within 4 days of receiving the Pfizer-BioNTech COVID-19 vaccine (12). A recent series detailing immune-mediated disease flares after mRNA vaccination also reported two cases of pericarditis (13).

As of June 2021, the Vaccine Adverse Event Reporting System (VAERS) has documented 518 confirmed cases of myocarditis or pericarditis after mRNA-based COVID-19 vaccination in patients 30 years of age or younger (14). Most developed symptoms within 1 week of vaccination, were predominantly male, and symptoms were more likely to develop after the second dose. Most required hospitalization, though they recovered well with standard treatment.

Although no mechanistic basis has been characterized describing the link between pericarditis and vaccination, it is suspected to be due to a high level of systemic reactogenicity and immunogenicity to the vaccine. The observation that younger patients experience more side effects after vaccination and that their neutralizing antibody titers reach higher levels than their adult counterparts supports this theory (15). It is imperative that cases of myopericarditis after vaccination for COVID-19 be reported to VAERS. As case reports can only suggest an association and not establish causality, despite our experience with this case, we agree with the CDC recommendation that the benefits outweigh the risks of vaccination and should continue to be offered to everyone who is eligible (16).

Why Should an Emergency Physician Be Aware of This?

Mass vaccination is considered the cornerstone for ending the COVID-19 pandemic, and as more people and new populations are vaccinated, new adverse events are being documented. It is important for emergency physicians to be aware of the association between mRNA-based COVID-19 vaccination and myopericarditis, ensure these patients get the appropriate evaluation and treatment, and

ensure that these cases are reported to the appropriate public health officials.

References

1. U.S. Food and Drug Administration (FDA). FDA approves first treatment for disease that causes recurrent inflammation in sac surrounding heart. 2021. Available at: <https://www.fda.gov/drugs/drug-safety-and-availability/fda-approves-first-treatment-disease-causes-recurrent-inflammation-sac-surrounding-heart>. Accessed July 1, 2021.
2. Chan TC, Brady WJ, Pollack M. Electrocardiographic manifestations: acute myopericarditis. *J Emerg Med* 1999;17:865–72.
3. Buttà C, Zappia L, Latorra G, Roberto M. Diagnostic and prognostic role of electrocardiogram in acute myocarditis: a comprehensive review. *Ann Noninvasive Electrocardiol* 2020;25:e12726.
4. Seferović PM, Ristić AD, Maksimović R, et al. Pericardial syndromes: an update after the ESC guidelines 2004. *Heart Fail Rev* 2013;18:255–66.
5. Durani Y, Giordano K, Goudie BW. Myocarditis and pericarditis in children. *Pediatr Clin North Am* 2010;57:1281–303.
6. LeWinter MM. Clinical practice. Acute pericarditis. *N Engl J Med* 2014;371:2410–16.
7. Adler Y, 2015 Charron P. The ESC Guidelines on the diagnosis and management of pericardial diseases. *Eur Heart J* 2015;36:2873–4.
8. Imazio M, Belli R, Brucato A, et al. Efficacy and safety of colchicine for treatment of multiple recurrences of pericarditis (CORP-2): a multicentre, double-blind, placebo-controlled, randomised trial. *Lancet* 2014;383:2232–7.
9. Mei R, Raschi E, Poluzzi E, Diemberger I, De Ponti F. Recurrence of pericarditis after influenza vaccination: a case report and review of the literature. *BMC Pharmacol Toxicol* 2018;19:20.
10. Eckart RE, Love SS, Atwood JE, et al. Incidence and follow-up of inflammatory cardiac complications after smallpox vaccination. *J Am Coll Cardiol* 2004;44:201–5.
11. Kuntz J, Crane B, Weinmann S, Naleway AL. Vaccine Safety Datalink Investigator Team. Myocarditis and pericarditis are rare following live viral vaccinations in adults. *Vaccine* 2018;36:1524–1527.
12. Marshall M, Ferguson ID, Lewis P, et al. Symptomatic acute myocarditis in 7 adolescents following Pfizer-BioNTech COVID-19 vaccination. *Pediatrics* 2021;148 e2021052478.
13. Watad A, De Marco G, Mahajna H, et al. Immune-mediated disease flares or new-onset disease in 27 subjects following mRNA/DNA SARS-CoV-2 vaccination. *Vaccines (Basel)* 2021;9:435.
14. Centers for Disease Control and Prevention (CDC). Selected adverse events reported after COVID-19 vaccination. Available at: <https://labeling.pfizer.com/ShowLabeling.aspx?id=14471&format=pdf>. Accessed July 1, 2021.
15. Pfizer. Fact sheet for healthcare providers administering vaccine (vaccination providers). Emergency use authorization (EUA) of the Pfizer-BioNTech COVID-19 vaccine to prevent Coronavirus disease 2019 (COVID-19). 2021. Available at: <https://labeling.pfizer.com/ShowLabeling.aspx?id=14471>. Accessed November 9, 2021.
16. Centers for Disease Control and Prevention (CDC). Myocarditis and pericarditis following mRNA COVID-19 vaccination. 2021. Available at: [cdc.gov/coronavirus/2019-ncov/vaccines/safety/myocarditis.html](https://www.cdc.gov/coronavirus/2019-ncov/vaccines/safety/myocarditis.html). Accessed August 18, 2021.