

Alopecia Areata Treated with Advanced Platelet-rich Fibrin Using Micronization

Oscar Adrian Vazquez, MD, MS*

Rachel H. Safeek, MPH†

Jacob Komberg, BS*

Hilton Becker, MD, FACS, FRCS*

Summary: Platelet-rich plasma (PRP) has been shown to release a multitude of growth factors, but its preparation requires the use of anticoagulants. In contrast, advanced platelet-rich fibrin (aPRF) is produced by centrifuging whole blood and allowing it to clot. The clot contains the platelets, growth factors, and neutrophils, and it is composed of a fibrin matrix that continuously releases more growth factors over a longer time period. Advanced PRF is commonly used in dental and bone grafting procedures, but it is rarely used for cosmetic injectables because its high density makes it difficult to inject through smaller gauge needles. A technique is described whereby aPRF is reduced to an injectable form with micronization and used to treat alopecia areata (AA) in a 28-year-old patient who developed it after symptomatic COVID-19 infection a month before presentation. The patient was vaccinated in between infection, and symptoms were limited to headache and sore throat. He had complete resolution of his AA at 6-month follow-up with only two treatments as opposed to monthly intralesional steroids. We report our results using aPRF for AA with promising results as a possible future treatment for patients with this autoimmune disease. (*Plast Reconstr Surg Glob Open* 2022;10:e4032; doi: [10.1097/GOX.0000000000004032](https://doi.org/10.1097/GOX.0000000000004032); Published online 18 January 2022.)

Platelet-rich plasma (PRP), which contains growth factors important for cell proliferation and differentiation and has anti-inflammatory properties, may be more beneficial in some patients with alopecia areata (AA) as opposed to first-line therapy.¹ First introduced in 2003 and expanded upon in 2006, platelet-rich fibrin (PRF) has been reclassified into both injectable PRF (iPRF) and advanced PRF (aPRF), with aPRF containing an increased number of neutrophils which can contribute to monocyte/macrophage differentiation and help in tissue repair and vessel formation.^{2–4} Further, aPRF is produced by centrifuging whole blood for less time at an increased rpm, withdrawing the use of anticoagulants, and allowing it to clot.⁵ The clot contains platelets and growth factors and is composed of a fibrin matrix that continuously releases more growth factors over a longer period.⁶ Although aPRF is commonly used in dental and bone grafting procedures, it is rarely used for cosmetic injectables because its high density makes it difficult to inject

through smaller gauge needles.⁷ Here, we present a case of a patient with AA after COVID-19 infection who was successfully treated with aPRF injections with the use of micronization (cutting the aPRF with a blade in between a Luer-to-Luer connector).

PRF PREPARATION

Written informed consent was obtained from the patient, and the principles stated in the 2013 Declaration of Helsinki were strictly followed. Equal amounts of blood were drawn into four 10 mL vacutainer red top tubes (BD, Franklin Lakes, N.J.). Advanced PRF clots were prepared from the patient's whole blood by centrifugation without anticoagulant at 2800 rpm for 5 min. The centrifuged sample consisted of upper straw-colored acellular plasma, the aPRF clot in the middle layer, and the red-colored bottom layer containing red blood cells. The top supernatant was discarded and, using sterile forceps, the aPRF clots were placed into a 3-cm³ syringe. The 3-cm³ syringe was connected to another 3-cm³ syringe using a 2.4-mm Luer-to-Luer connector (Tulip Medical, San Diego, Calif.) with a 15 blade through the middle of it for micronization. The aPRF clots were passed in between syringes four times to micronize the clots into an injectable solution (Fig. 1). This was able to be injected using a 20-gauge needle with an internal diameter of 0.603-mm (BD, Franklin Lakes, N.J.).

From the *Department of Surgery at Charles E. Schmidt College of Medicine, Florida Atlantic University, Boca Raton, Fla.; and †University of Louisville School of Medicine, Louisville, Ky.

Received for publication September 30, 2021; accepted November 8, 2021.

Copyright © 2022 The Authors. Published by Wolters Kluwer Health, Inc. on behalf of The American Society of Plastic Surgeons. This is an open-access article distributed under the terms of the [Creative Commons Attribution-Non Commercial-No Derivatives License 4.0 \(CCBY-NC-ND\)](https://creativecommons.org/licenses/by-nc-nd/4.0/), where it is permissible to download and share the work provided it is properly cited. The work cannot be changed in any way or used commercially without permission from the journal.

DOI: [10.1097/GOX.0000000000004032](https://doi.org/10.1097/GOX.0000000000004032)

Disclosure: Dr. Hilton Becker, MD is a consultant for Marina Medical and Mentor Worldwide, LLC., and Scientific Advisor for Surgical Innovation Associates. The other authors have nothing to disclose. No funding was received for this article.

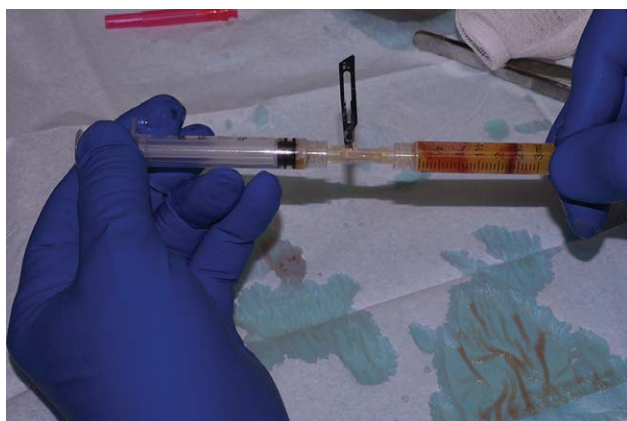

Fig. 1. Micronization of PRF into injectable form using a blade in a Luer-to-Luer connector.

CASE PRESENTATION

The patient is a 28-year-old man with no medical or surgical history who presented to clinic on March 10th with two hairless spots consistent with AA of the occipital region (Fig. 2). He first noticed the spots after a haircut two weeks prior. He has no family history of any autoimmune disorders. The patient received the first Moderna vaccine dose on January 14, 2021 and the second dose on March 1, 2021. In between doses, the patient had symptomatic COVID-19 infection, for which he tested positive on January 22, 2021. His only symptoms were headache and sore throat of three days duration with no fever, chills, cough, shortness of breath, ageusia, or anosmia. Patient was treated with aPRF injections with the use of micronization as described above. The first treatment was on March 10, 2021 and a second intralésional session was performed on May 4, 2021 (Fig. 3). There was resolution at follow-up on September 13, 2021 (Fig. 4). He used no other treatments during this time.

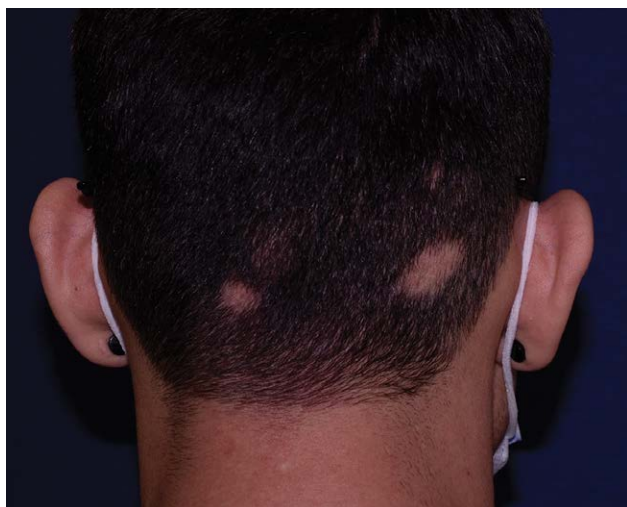


Fig. 2. A 28-year-old man who presented with AA in two spots in the occipital region.

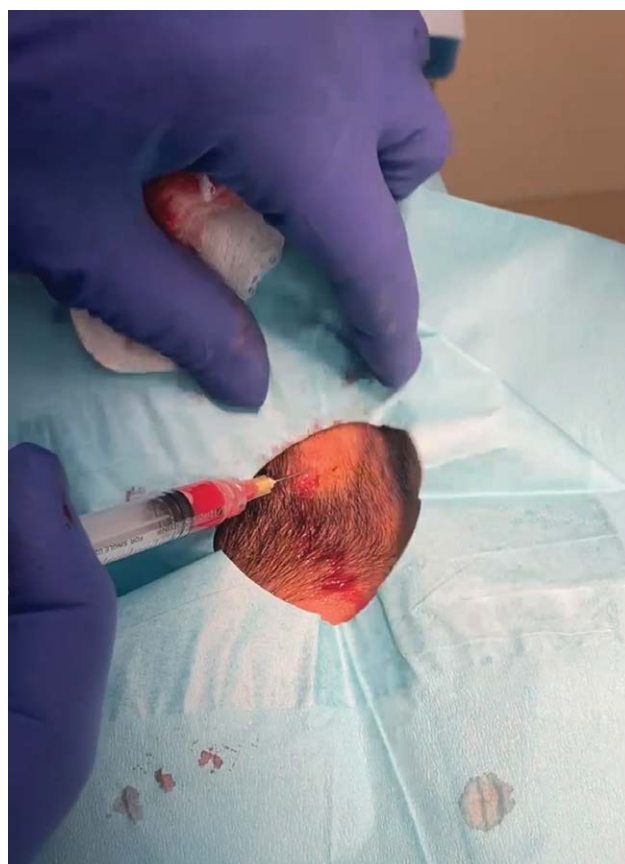


Fig. 3. Intralésional injection of PRF.

DISCUSSION

AA is believed to be among the most common autoimmune conditions in humans, with an estimated lifetime risk of 1.7%–2.1%.⁸ COVID-induced AA has emerged as a novel documented sequela of the virus in at least four other patients in two different studies, with one study noting the rapidly progressive nature and unresponsiveness to 1–2 months of topical, intralésional, and/or nutritional

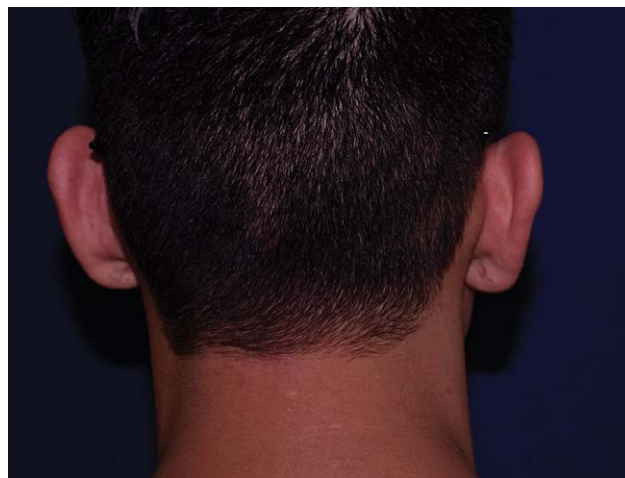

Fig. 4. Six months after two treatments of intralésional PRF.

treatments.^{9,10} We mention this because our patient had no medical history and no family history of any autoimmune diseases before his first episode of AA. However, more research is needed to prove AA as a probable result of COVID-19 infection.

After a literature search with the terms “PRF,” “alopecia areata,” “alopecia,” and other modifiers on PubMed, EMBASE, and Google Scholar, we identified four prior studies that have been published using PRF for the treatment of alopecia, but their approach is different than ours as they were all done for the treatment of androgenetic alopecia and three of them used iPRF instead of aPRF. The earliest study in 2014 treated androgenetic alopecia using “platelet-rich fibrin matrix,” which was spun at 1100g for 6 minutes first using proprietary thixotropic separator gel tubes and transferred to a closed-vacuum tube after adding calcium chloride. The solution was injected within 8–10 minutes of activation “before a solid fibrin mesh with adherent platelets develops.”¹¹ This is different from our approach as we form the fibrin mesh containing the leukocytes as aPRF.

A large study published in 2018 of 168 patients using iPRF for androgenetic alopecia reported good outcomes, but it used a two-step process for the creation of iPRF using anticoagulant spinning at 1500rpm for 5 minutes followed by filtration through a filter.¹² Two studies used iPRF spun at speeds ranging from 700 to 800rpm for a time of 4 minutes in small case series of three and four cases, respectively.^{13,14} These four studies are different from our patient as we are treating alopecia areata and not androgenetic alopecia. We do this by using aPRF formed by centrifugation at a higher speed of 2800rpm for 5 minutes to form the fibrin mesh, which we then micronize for intralesional injection.

The preferred initial treatment for AA in patients with limited bald spots typically consists of intralesional and/or topical corticosteroids.¹⁵ Results reported include complete regrowth of hair after 4 months in 40 of 62 patients (63%) treated with monthly injections of triamcinolone acetonide.¹⁶ Other first-line treatments include topical immunologics, or systemic corticosteroid therapy. Anthralin is second-line therapy. Janus kinase inhibitors, methotrexate, azathioprine, sulfasalazine, and cyclosporine are reserved for refractory disease. Alternative therapies include minoxidil, lasers, and PRP.¹⁵

PRF has been shown to continuously release large amounts of growth factors for up to 28 days which makes it an ideal treatment for AA.¹⁷ Through micronization, it is possible to convert the aPRF clot into a particle size injectable through a smaller gauge needle, similar to fat grafting.¹⁸ This allows for the quick preparation of the solutions for injection using the patient’s blood without anticoagulants, the added benefits of increased growth factors, and the flexibility of injecting with smaller needles as the PRF matrix is too thick for standard injection needles compared with PRP. Although alopecia areata is self-resolving in 50% of cases within a year, typical treatment consists of monthly injections with intralesional steroids due to its recurrence, and our patient had similar results with two treatments almost 2 months apart. Ultimately,

more trials are needed comparing the benefits of PRF versus PRP in the treatment of AA, and we are in the process of developing a single-use device for micronization from the proposed mechanism used.

Oscar Adrian Vazquez, MD, MS

777 Glades Rd, BC-71

Boca Raton, FL 33431

E-mail: ovazquez2017@health.fau.edu

REFERENCES

1. Trink A, Sorbellini E, Bezzola P, et al. A randomized, double-blind, placebo- and active-controlled, half-head study to evaluate the effects of platelet-rich plasma on alopecia areata. *Br J Dermatol*. 2013;169:690–694.
2. Dohan D, Donsimoni JM, Navarro G, et al. Platelet concentrates. Part I: technologies. *Implantodontie*. 2003;12:5–16.
3. Dohan DM, Choukroun J, Diss A, et al. Platelet-rich fibrin (PRF): a second-generation platelet concentrate. Part II: 17. Platelet-related biologic features. *Oral Surg Oral Med Oral Pathol Oral Radiol Endod*. 2006;101:e45–e50.
4. Ghanaati S, Booms P, Orlowska A, et al. Advanced platelet-rich fibrin: a new concept for cell-based tissue engineering by means of inflammatory cells. *J Oral Implantol*. 2014;40:679–689.
5. Kobayashi M, Kawase T, Okuda K, et al. In vitro immunological and biological evaluations of the angiogenic potential of platelet-rich fibrin preparations: a standardized comparison with PRP preparations. *Int J Implant Dent*. 2015;1:31.
6. Kobayashi E, Flückiger L, Fujioka-Kobayashi M, et al. Comparative release of growth factors from PRP, PRF, and advanced-PRF. *Clin Oral Investig*. 2016;20:2353–2360.
7. Fan Y, Perez K, Dym H. Clinical uses of platelet-rich fibrin in oral and maxillofacial surgery. *Dent Clin North Am*. 2020;64:291–303.
8. Mirzoyev SA, Schrum AG, Davis MDP, et al. Lifetime incidence risk of alopecia areata estimated at 2.1% by Rochester Epidemiology Project, 1990–2009. *J Invest Dermatol*. 2014;134:1141–1142.
9. Rossi A, Magri F, Michelini S, et al. New onset of alopecia areata in a patient with SARS-CoV-2 infection: possible pathogenetic correlations? *J Cosmet Dermatol*. 2021;20:2004–2005.
10. Flvenson D. COVID-19: association with rapidly progressive forms of alopecia areata. *Int J Dermatol*. 2021;60:127.
11. Sclafani AP. Platelet-rich fibrin matrix (PRFM) for androgenetic alopecia. *Facial Plast Surg*. 2014;30:219–224.
12. Schiavone G, Paradisi A, Ricci F, et al. Injectable platelet-, leukocyte-, and fibrin-rich plasma (iL-PRF) in the management of androgenetic alopecia. *Dermatol Surg*. 2018;44:1183–1190.
13. Arora R, Shukla S. Injectable-platelet-rich fibrin-smart blood with stem cells for the treatment of alopecia: a report of three patients. *Int J Trichology*. 2019;11:128–131.
14. Shashank B, Bhushan M. Injectable platelet-rich fibrin (PRF): the newest biomaterial and its use in various dermatological conditions in our practice: a case series. *J Cosmet Dermatol*. 2021;20:1421–1426.
15. Messenger AG. Alopecia areata: management In: Post TW, Rutgeerts P and Grover S, eds. *UpToDate*. Riverwoods, IL: Wolters Kluwer; 2021. Available at <https://www.uptodate.com/contents/alopecia-areata-management#H37>. Accessed September 20, 2021.
16. Kubeyinje EP. Intralesional triamcinolone acetonide in alopecia areata amongst 62 Saudi Arabs. *East Afr Med J*. 1994;71:674–675.
17. Yu P, Zhai Z, Lu H, et al. Platelet-rich fibrin improves fat graft survival possibly by promoting angiogenesis and adipogenesis, inhibiting apoptosis, and regulating collagen production. *Aesthet Surg J*. 2020;40:NP530–NP545.
18. Vazquez OA, Markowitz MI, Becker H. Fat graft size: relationship between cannula and needle diameters. *Cureus*. 2020;12:e7598.