



Since January 2020 Elsevier has created a COVID-19 resource centre with free information in English and Mandarin on the novel coronavirus COVID-19. The COVID-19 resource centre is hosted on Elsevier Connect, the company's public news and information website.

Elsevier hereby grants permission to make all its COVID-19-related research that is available on the COVID-19 resource centre - including this research content - immediately available in PubMed Central and other publicly funded repositories, such as the WHO COVID database with rights for unrestricted research re-use and analyses in any form or by any means with acknowledgement of the original source. These permissions are granted for free by Elsevier for as long as the COVID-19 resource centre remains active.



Case Report

A case of fatal multi-organ inflammation following COVID-19 vaccination



Hideyuki Nushida^{a,*}, Asuka Ito^a, Hiromitsu Kurata^{a,b}, Hitomi Umemoto^{a,c}, Itsuo Tokunaga^a, Hirofumi Iseki^{a,b}, Akiyoshi Nishimura^a

^a Department of Forensic Medicine, Institute of Biomedical Sciences, Tokushima University Graduate School, Tokushima, Japan

^b Department of Physical Medicine, Nakazu-Yagi Hospital, Tokushima, Japan

^c Division of Anatomical Education Support, Tokushima University Graduate School, Tokushima, Japan

ARTICLE INFO

Keywords:

Systemic inflammation
Myopericarditis
COVID-19
Vaccines
Sudden death
Autopsy

ABSTRACT

A 14-year-old Japanese girl died unexpectedly 2 days after receiving the third dose of the BNT1262b2 mRNA COVID-19 vaccine. Autopsy findings showed congestive edema of the lungs, T-cell lymphocytic and macrophage infiltration in the lungs, pericardium, and myocardium of the left atria and left ventricle, liver, kidneys, stomach, duodenum, bladder, and diaphragm. Since there was no preceding infection, allergy, or drug toxicity exposure, the patient was diagnosed with post-vaccination pneumonia, myopericarditis, hepatitis, nephritis, gastroenteritis, cystitis, and myositis. Although neither type of inflammation is fatal by itself, arrhythmia is reported to be the most common cause of death in patients with atrial myopericarditis. In the present case, arrhythmia of atrial origin was assumed as the cause of cardiac failure and death. In sudden post-vaccination deaths, aggressive autopsy systemic search and histological examination involving extensive sectioning of the heart, including the atrium, are indispensable.

1. Introduction

Coronavirus disease 2019 (COVID-19) vaccines are available worldwide. Since their introduction, post-vaccination deaths have been reported, and their association with the vaccine has been forensically examined [1,2]. Post-vaccination myocarditis and pericarditis have been increasingly reported, with male adolescents reported to have a higher incidence of pericarditis with a good prognosis, while middle-aged and older patients are more likely to have severe myocarditis. In this study, we report an autopsy case of a 14-year-old girl who died unexpectedly 2 days after receiving the third dose of BNT1262b2 mRNA COVID-19 vaccine.

2. Case report

A 14-year-old Japanese girl received a third dose of the BNT1262b2 mRNA COVID-19 vaccine/Pfizer (Comirnaty®) on 10th August 2022. Despite her history of orthostatic dysregulation, she was healthy by nature and was active in her middle school athletic team. The day after vaccination, she developed a fever of 37.9 °C, which resolved by the same evening. Her sister, who had slept with her that night, reported that she woke up briefly because she was having difficulty in breathing,

talked with her sister, and went to bed soon after. The following morning, her mother noticed that she was not breathing and had a pale appearance, and she immediately called an ambulance. The patient was in cardiopulmonary arrest when the ambulance crew arrived at their house and attempts to administer advanced life support were unsuccessful. She died 45 h after the third vaccination. After the first dose of vaccine on 12th September 2021, she had arm pain without fever. The day after the second dose on 3rd October 2021, she missed school because she had a fever of less than 38 °C. All three vaccines were made by Pfizer. An autopsy was performed the following day to evaluate the cause of sudden death.

2.1. Autopsy findings

The deceased patient was 154 cm tall and weighed 43 kg. The patient's body showed normal development and nutrition relative to her age. No superficial injuries were observed, except for injection marks from emergency medical treatment. No petechial hemorrhage was observed in the conjunctiva. Her heart weighed 192 g (normal weight, 241.92 ± 42.88 g) [3] and contained dark-red liquid blood (21 g on the left and 110 g on the right side). The heart showed no degeneration or scarring on the grossly superficial surface or cross-sections. The left lung

* Corresponding author.

E-mail address: nushida@tokushima-u.ac.jp (H. Nushida).

<https://doi.org/10.1016/j.legalmed.2023.102244>

Received 22 December 2022; Received in revised form 12 March 2023; Accepted 15 March 2023

Available online 20 March 2023

1344-6223/© 2023 Elsevier B.V. All rights reserved.

weighed 424 g (normal weight, 349.78 ± 143.69 g) [3], while the right lung weighed 471 g (normal weight, 396.28 ± 190.63 g) [3]. In the cross-section, both lungs showed severe pulmonary edema and congestion.

A COVID-19 antigen quantification test performed using a nasopharyngeal swab taken before autopsy yielded negative results. The serum collected at autopsy tested negative for adenovirus, cytomegalovirus, influenza virus (A, B), respiratory syncytial virus, Epstein-Barr virus, enterovirus (70, 71), parvovirus, and human immunodeficiency virus. Quantitative testing for the COVID-19 antigen using nasopharyngeal swabs yielded negative results. The results of polymerase chain reaction tests performed for COVID-19 using swabs from the lung, heart, liver, kidney, stomach, duodenum, diaphragm, and cerebrum after formalin fixation were also negative. Blood at autopsy was tested for drug toxicity using LC-MS/MS, and the results were negative.

2.2. Histological findings

The autopsied organs were examined histologically, focusing particularly on the resected heart, anterior and posterior walls of the left and right atria and ventricles, atrial septum, ventricular septum, sinus node, and atrioventricular node. Tissue samples were fixed in phosphate-buffered formalin and embedded in paraffin. Paraffin sections of 5 μ m thickness were then stained with hematoxylin and eosin. Lymphocyte cellular infiltrates, including eosinophils, were observed in the lungs, pericardium of both atria and adjacent myocardium, liver, kidneys, stomach, duodenum, and diaphragm (Fig. 1), and mild cellular infiltration was also observed in the pericardium of the right ventricle. The brain showed congestion. In the hippocampus a slight lymphocytic infiltration was observed. Immunostaining with an anti-CD3 antibody (Dako 1:200) (Fig. 1) and anti-CD68 antibody (Dako 1:200) (Fig. 1) revealed that most of the infiltrating cells were T cells and macrophages.

2.3. Biochemical analysis

Laboratory studies revealed elevated SARS-CoV-2 antibody (43600 U/mL, normal less than 0.80), elevated IL-6 (226 pg/mL, normal ≤ 4.0), slightly elevated C-reactive protein (0.910 mg/mL). IgE (30.8 IU/mL, normal ≤ 170) and C3 (126 mg/dL, normal 86–160) were within the normal range. The biochemical analysis was performed by SRL, Inc. (Tokyo, Japan).

2.4. Diagnosis

A diagnosis of vaccine-related multiple-organ inflammation was made based on the absence of bacterial or viral infection, lack of a past medical history suggestive of autoimmune disease, no allergic reaction, and no drug exposure other than the vaccine. Myopericarditis is a form of multiple-organ inflammation. Although pneumonia is involved, pneumonia alone is rarely a cause of sudden death, and the presence of erythrocyte-laden macrophages as well as congestive edema of the lungs on histology suggested signs of heart failure from the previous day. Although the extent of inflammation was relatively narrow, the presence of foci centered on the atria and breathlessness are the findings that raise the suspicion of heart failure several hours before death. This led to the diagnosis that the cause of death was vaccine-related myopericarditis, which led to severe arrhythmias and progressive heart failure.

3. Discussion

3.1. Death after COVID-19 vaccination:

Vaccine development and its widespread application are key elements in the fight against the COVID-19 pandemic. The COVID-19 vaccine is now used worldwide and has contributed to the containment of the pandemic. However, adverse events caused by vaccines have

been a problem. A forensic examination for the evaluation of the association between vaccination and death was conducted in cases of post-vaccination deaths [1,2,4]. The majority of these cases were negatively associated with vaccination; however, anaphylaxis, vaccine-induced immunothrombotic thrombocytopenia, myocarditis, and pericarditis have all been listed as having a suspected association with vaccination and vaccination-related death [2,4]. Murata et al. also reported four cases of death after vaccination, in which the only autopsy findings were organ congestion with no evidence of myocarditis. RNA analysis of the blood showed that neutrophil degranulation and cytokine signaling were upregulated in the control group, which led them to conclude that the deaths were due to cytokine storm [5].

3.2. Myocarditis and pericarditis after COVID-19 vaccination

Reports of myocarditis and pericarditis after COVID-19 vaccination have increased since the report by Albert et al. [6]. The frequency of occurrence of myocarditis and pericarditis has been reported in a US military survey including 23 cases of myocarditis/2,800,000 persons with a mean age of 25 years, all males, and no deaths [7]. A total of 40 U. S. hospitals reported 20 cases/2,000,287 with myocarditis and 37 cases/2,000,287 with pericarditis; both groups showed male predilection, mean age of onset of 36 years for myocarditis and 59 years for pericarditis, and no deaths in either group [8]. The Nordic cohort study reported that myocarditis occurred in 1,077/23,122,522 patients and pericarditis in 1,149/23,122,522 patients; both were more common in young men aged 16–24 years and most commonly occurred after the second vaccination [9]. Thus, post-vaccination myocarditis and pericarditis had incidence rates of 0.0008–0.0047% and 0.0019–0.0050%, respectively. Although usually mild, these conditions can occur; however, severe cases resulting in death are rare. As of September 2022, the number of COVID-19 vaccine recipients in Japan was approximately 103 million for the second dose and 82 million for the third dose [10]. Based on the above report, at least 800 cases of myocarditis and approximately 1,500 cases of pericarditis occurred after vaccination in Japan. Since the incidence of myocarditis and pericarditis is reported to be higher with second dose of the vaccine than with first dose [11], third dose of the vaccine are likely to further increase the frequency of occurrence of the disease.

The mechanism by which the COVID-19 vaccine causes myocarditis and pericarditis is unclear; however, several hypotheses have been proposed. The mRNA vaccine results in modifications to the nucleoside to reduce its antigenicity. In some individuals, mRNA is recognized as an antigen, resulting in the activation of the inflammatory cascades and immune pathways; in such cases, myocarditis occurs as part of a systemic inflammatory response [12,13]. Some researchers have also hypothesized that in some patients, the spike protein of the COVID-19 virus and an unknown protein in the myocardium are molecular mimics and that the vaccine elicits antibodies that damage the myocardium [14,15]. Others have hypothesized that the angiotensin-converting enzyme 2 receptor of myocytes binds to the glycoprotein of mRNA vaccines and causes hypersensitivity to myocytes [16].

Many histological features of myocarditis after COVID-19 vaccination have been reported, such as the infiltration of inflammatory cells, mostly including T cells and macrophages, mixed with the presence of eosinophils [2,16–21]. Neutrophilic infiltration [17,19], the appearance of mast cells [2], myocyte necrosis [18], and the coexistence of contraction bands [17,19] have also been observed. These findings are consistent with our findings of T cell- and macrophage-dominated cellular infiltrates mixed with eosinophilic cells but are not characteristic of post-vaccination myocarditis. Eosinophilic cells are said to appear in myocarditis following hypersensitivity reactions to drugs or other substances [22], and other histological features are also influenced by cardiac diseases such as myocardial ischemia and mitral valve regurgitation before vaccination as well as the course of the disease leading to death [2,21]. In the present case, the patient showed a similar

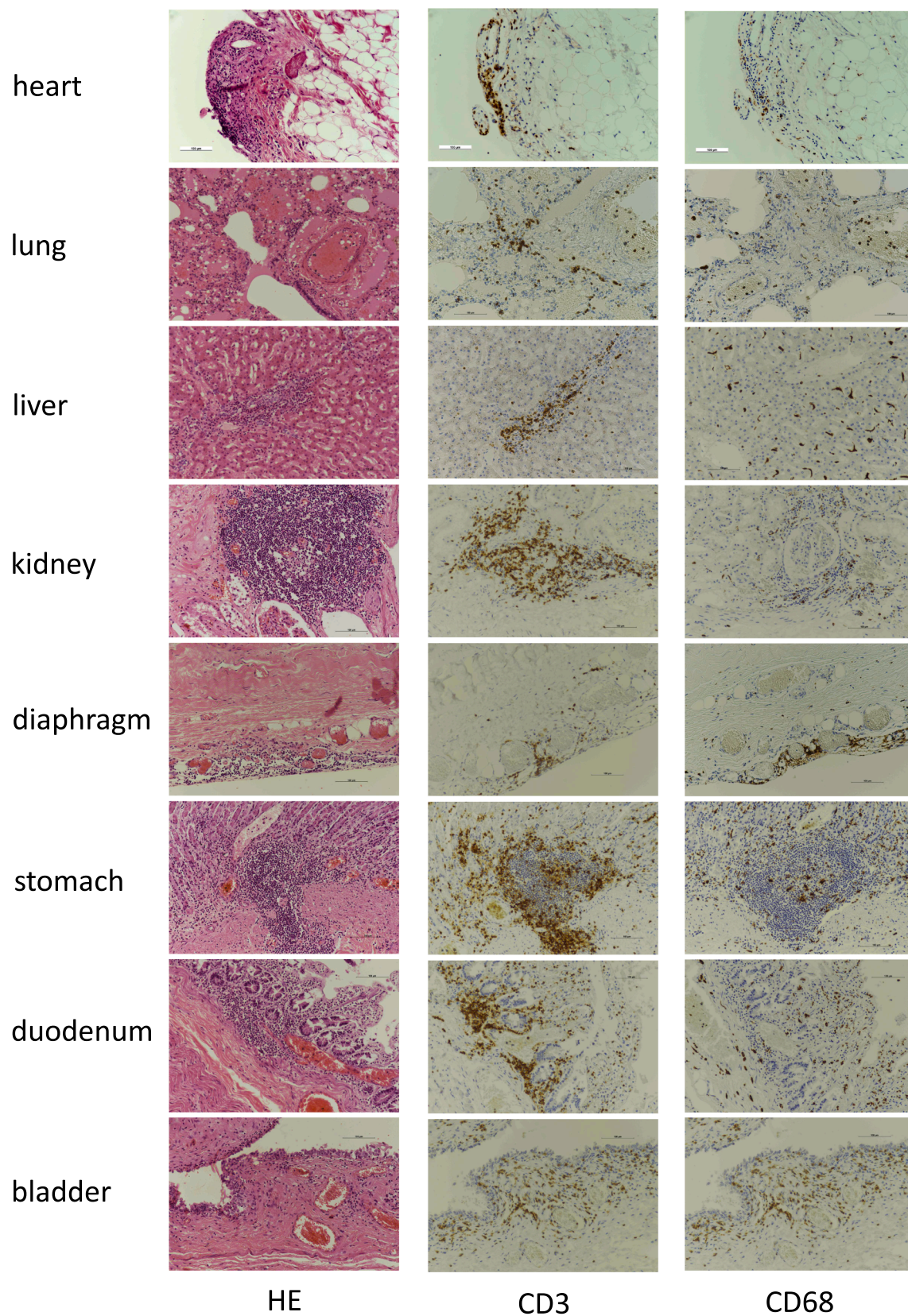


Fig. 1. Histopathology of the heart (left atrium), lung, liver, kidney, diaphragm, stomach, duodenum, and bladder. All images are $\times 200$ magnification. HE: Hematoxylin and eosin staining showing lymphocytic infiltration. CD3: Immunohistochemical staining for CD3 showing inflammatory cells including CD3-positive T-cells. CD68: Immunohistochemical staining for CD68 shows the infiltrating cells include macrophages.

inflammatory cell infiltrate in the myopericardium as well as in the lungs, liver, kidney, stomach, duodenum, diaphragm, and brain, thus indicating systemic inflammation. Reports of neutrophil degranulation and upregulation of cytokine signaling in the RNA sequences of post-vaccination deaths have also suggested that post-vaccination cytokine upregulation triggers systemic inflammation [3]. This is consistent with the increase in lymphocytes due to the degranulation of neutrophils and an increase in cytokines. These factors may also explain the fever, malaise, and arthralgia, which are common adverse reactions after vaccination.

3.3. Death due to atrial myocarditis and pericarditis

In our case, inflammation of the heart was primarily found in the bilateral atria. Deaths due to myopericarditis are often caused by heart failure resulting from extensive damage to the myocardium, including the ventricles [20]. In the past, three deaths due to myocarditis in the atria alone have been reported, all of which were considered deaths due to arrhythmias caused by the extension of inflammation into the stimulatory conduction system, resulting in heart failure [17,23,24]. In a routine autopsy, the atria are rarely excised for histological examination of the heart, and often, only the ventricles are examined. However, when investigating the cause of death in cases of sudden death, such as the present case, it has been pointed out that if there are no gross changes, histological examination of the ventricles alone may increase the risk of missing lesions confined to the atria [19,23,24]. Complete histological examination of the heart, including the atria, is important in the absence of an obvious gross cause of death at autopsy.

Declaration of Competing Interest

The authors declare that they have no known competing financial interests or personal relationships that could have appeared to influence the work reported in this paper.

References

- [1] C. Edler, A. Klein, A.S. Schröder, J.P. Sperhake, B. Ondruschka, Deaths associated with newly launched SARS-CoV-2 vaccination (Comirnaty®), *Legal Med* 51 (2021), 101895.
- [2] J. Schneider, L. Sottmann, A. Greinacher, M. Hagen, H.U. Kasper, C. Kuhnen, S. Schlepper, S. Schmidt, R. Schulz, T. Thiele, C. Thomas, A. Schmeling, Postmortem investigation of fatalities following vaccination with COVID-19 vaccines, *Int J Legal Med* 135 (2021) 2335–2345.
- [3] A. Yeo, B. Kuek, M. Lau, S.R. Tan, S. Chan, Post COVID-19 vaccine deaths – Singapore's early experience, *Forensic Sci Int* 332 (2022) 11199.
- [4] Planning and Investigation Committee of the Japanese Society of Legal Medicine. Weights and sizes of internal organs measured in forensic autopsy cases from 2009 to 2013 in Japan. (in Japanese). Questionnaire research performed by the Japanese society of legal medicine. 2015, URL: <http://www.jslm.jp/problem/zouki.pdf>.
- [5] Murata K, Nakao N, Ishiuchi N, Fukui T, Katsuya N, Fukumoto W, Oka H, Yoshikawa N, Nagao T, Namera A, Kakimoto N, Oue N, Awai K, Yoshimoto K, Nagao M. Four cases of cytokine storm after COVID-19 vaccination: Case report. *Front Immunol* 13:967226. doi:10.3389/fimmu.2022.967226.
- [6] E. Albert, G. Aurigemma, J. Saucedo, D.S. Gerson, Myocarditis following COVID-19 vaccination, *Radiol Case Report* 16 (2021) 2142–2145.
- [7] J. Montgomery, M. Ryan, R. Engler, D. Hoffman, B. McClenathan, L. Collins, D. Loran, D. Hrnir, K. Herring, M. Platzer, N. Adams, A. Sanou, L.T. Cooper, Myocarditis following immunization with mRNA COVID-19 vaccines in members of the US military, *JAMA Cardiol* 6 (10) (2021) 1202–1206.
- [8] G.A. Diaz, G.T. Parsons, S.K. Gering, A.R. Meier, I.V. Hutchinson, A. Robicsek, Myocarditis and pericarditis after vaccination for COVID-19, *JAMA* 326 (12) (2021) 1210–1212.
- [9] O. Karlstad, P. Hovi, A. Husby, T. Härkänen, R.M. Selmer, N. Pihlström, J. V. Hansen, H. Nohynek, N. Gunnes, A. Sundström, J. Wohlfahrt, T.A. Nieminen, M. Grünewald, H.L. Gulseth, A. Hviid, R. Ljung, SARS-CoV-2 vaccination and myocarditis in a Nordic cohort study of 23 million residents, *JAMA Cardiol* 7 (6) (2022) 600–612.
- [10] COVID-19 Vaccines. Ongoing topics. Prime minister of Japan and his cabinet. <https://japan.kantei.go.jp/ongoingtopics/vaccine.html/> (accessed 2022-9-9).
- [11] B. Bozkurt, I. Kamat, J. Hotez, Myocarditis with COVID-19 mRNA vaccines, *Circulation* 144 (6) (2021) 471–484.
- [12] K. Karikó, M. Buckstein, H. Ni, D. Weissman, Suppression of RNA recognition by Toll-like receptors: the impact of nucleoside modification and the evolutionary origin of RNA, *Immunity* 23 (2) (2005) 165–175.
- [13] F. Caso, L. Costa, P. Ruscitti, L. Navarini, A.D. Puente, R. Giacomelli, R. Scarpa, Could Sars-coronavirus-2 trigger autoimmune and/or autoinflammatory mechanisms in genetically predisposed subjects? *Autoimmun Rev* 19 (5) (2020), 102524.
- [14] Y. Segal, Y. Shoenfeld, Vaccine-induced autoimmunity: the role of molecular mimicry and immune crossreaction, *Cell Mol Immunol* 15 (2018) 586–594.
- [15] K. Larsen, E. Ammirati, L.T. Cooper, K.N. Hong, G. Saponara, D. Couri, A. Cereda, A. Procopio, C. Cavalotti, F. Oliva, T. Sanna, V.A. Ciconte, G. Onyango, D. R. Holmes, D.D. Borgeson, Myocarditis after BNT162b2 and mRNA-1273 vaccination, *Circulation* 144 (2021) 506–508.
- [16] S. Choi, S. Lee, J.W. Seo, M.J. Kim, Y.H. Jeon, J.H. Park, J.K. Lee, N.S. Yeo, Myocarditis-induced sudden death after BNT162b2 mRNA COVID-19 vaccination in Korea: Case report focusing on histopathological findings, *J Korean Med Sci* 36 (40) (2021) e286.
- [17] K.A. Verma, K.J. Lavine, C.Y. Lin, Myocarditis after Covid-19 mRNA vaccination, *N Engl J Med* 385 (2021) 1332–1334.
- [18] R. Ameratunga, S.T. Woon, M.N. Sheppard, J. Garland, B. Ondruschka, C.X. Wong, R.A.H. Stewart, M. Tatley, S.R. Stables, R.D. Tse, First identified case of fatal fulminant necrotizing eosinophilic myocarditis following the initial dose of the Pfizer-BioNTech mRNA COVID-19 vaccine (BNT162b2, Comirnaty): an extremely rare idiosyncratic hypersensitivity reaction, *J Clin Immunol* 42 (2022) 441–447.
- [19] J.R. Gill, R. Tashjian, E. Duncanson, Autopsy histopathologic cardiac findings in 2 adolescents following the second COVID-19 vaccine dose, *Arch Pathol Lab Med* 146 (8) (2022) 925–929.
- [20] S. Kazama, T. Okumura, Y. Kimura, R. Ito, T. Araki, T. Mizutani, H. Oishi, T. Kuwayama, H. Hiraiwa, T. Kondo, R. Morimoto, T. Saeki, T. Murohara, Biopsy-proven fulminant myocarditis requiring mechanical circulatory support following COVID-19 mRNA vaccination, *CJC Open* 4 (2022) 501–505.
- [21] N. Hoshino, M. Yanase, T. Ichiyasu, K. Kuwahara, H. Kawai, T. Muramatsu, H. Ishii, T. Tsukamoto, S. Morimoto, H. Izawa, An autopsy case report of fulminant myocarditis: Following mRNA COVID-19 vaccination, *J Cardiol Cases* 26 (6) (2022) 391–394, <https://doi.org/10.1016/j.jccase.2022.06.006>.
- [22] A.M.A. Ali, L.P. Straatman, M.F. Allard, A.P. Ignaszewski, Eosinophilic myocarditis: Case series and review of literature, *Can J Cardiol* 22 (14) (2006) 1233–1237.
- [23] R. Tse, J. Garland, K. Kesha, Y. Triggs, L. Modahl, D. Milne, Z. Yap, S. Stables, A rare case of isolated atrial myocarditis causing death with no postmortem computed tomography scan correlation, *Am J Forensic Med Pathol* 39 (2) (2018) 123–125.
- [24] M. Duffy, K. O'Connor, D. Milne, B. Ondruschka, R. Tse, J. Garland, Isolated atrial neutrophilic myocarditis: A rare cause of death and potential “blind spot” for postmortem computed tomography and postmortem examination, *Am J Forensic Med Pathol* 43 (1) (2022) 73–75.