

## Neuralgic amyotrophy in COVID-19 infection and after vaccination

### Dear Editor,

Various neurological manifestations associated with coronavirus disease 2019 (COVID-19) have been described,<sup>1</sup> conditions which left a significant proportion of patients with permanent disability. Continued vigilance is crucial with emergence of new severe acute respiratory syndrome coronavirus 2 (SARS-CoV-2) variants that cause the disease. Vaccination against COVID-19 remains the key strategy to reduce disease severity and transmission.<sup>2</sup> However, the novel mRNA technology and reports of neurological adverse effects raise concerns about COVID-19 vaccine safety, especially since multiple doses are needed to combat the waning immunity of such vaccines.<sup>3</sup>

Neuralgic amyotrophy (NA), or Parsonage-Turner syndrome/brachial neuritis, is characterised by male predisposition, severe pain and limb weakness in the 3rd to 7th decade of life.<sup>4</sup> It has rarely been reported in COVID-19 infections or within 6 weeks of vaccination.<sup>5</sup> Hypothesised causes focus on immune-mediated processes,<sup>3</sup> although the underlying pathophysiology remains unclear. With the COVID-19 pandemic, the challenge lies in differentiating the trigger for NA in vaccinated individuals who develop breakthrough COVID-19 infections. Comparisons of disease characteristics in COVID-19 patients with those occurring after COVID-19 vaccinations may shed some light, but such data are lacking. We illustrate a case and review the literature by searching PubMed, Embase and Google Scholar from 1 December 2019 to 30 November 2021 using the following keywords: “Parsonage-Turner Syndrome”, “brachial plexopathy”, “brachial neuritis”, “brachial plexitis”, “neuralgic amyotrophy”, “SARS-CoV-2” and “COVID-19”. We analysed cases with confirmed COVID-19 (World Health Organization guidelines)<sup>6</sup> occurring in symptomatic individuals and in those presenting within 6 weeks of COVID-19 vaccination (time frame conventionally used to study vaccine-related adverse events).<sup>7</sup> Cases with inadequate data, unclear temporality and non-English reports were excluded. The study was approved by the Singapore Health Services institutional review board (CIRB 2020/2410), and waiver of consent was granted.

A 34-year-old healthy man presented on day 4 of symptomatic COVID-19 with a 3-day history of shoulder pain, weakness and numbness of the left upper limb. There was no trauma, recent neck manipulation nor other constitutional symptoms. He had received the

Moderna mRNA-1273 vaccines on 3 and 24 July 2021, approximately 4 months prior to his presentation.

Clinical examination revealed diminished left biceps reflex, weakness of the left shoulder, elbow, wrist and finger movements (Medical Research Council [MRC] scale grade 3), as well as patchy numbness of the left arm, forearm and anatomical snuffbox, raising the suspicion of NA. There was no winging of the scapula.

Investigations including full blood count, serum electrolytes, liver enzymes, erythrocyte sedimentation rate, C-reactive protein and chest X-ray were unremarkable. A contrast-enhanced magnetic resonance imaging (MRI) of the brachial plexus (Figs. 1A and 1B), performed on day 3 of neurological symptoms, showed increased signal along the course of the distal trunks and divisions of the left brachial plexus, consistent with the clinical suspicion. MRI cervical spine showed mild spondylosis.

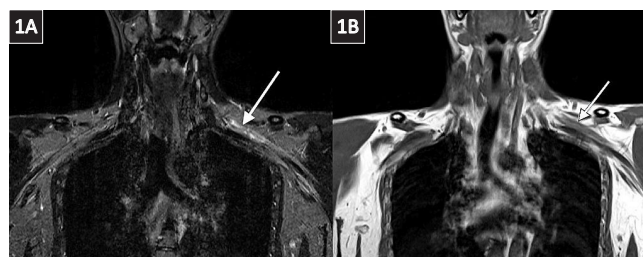


Fig. 1. (A) Magnetic resonance imaging (MRI) of brachial plexus coronal short tau inversion recovery (STIR) sequence shows mildly increased signal along the course of the distal trunks and divisions of the left brachial plexus (white arrow). (B) MRI of coronal T1 sequence shows partial effacement of intervening fat planes between the nerves (white arrow), indicating inflammation in all trunks, divisions and cords of the brachial plexus.

He improved remarkably on day 13 with conservative management. Pain and numbness resolved, while motor power improved to approximately MRC grade 4 across all ranges of motion. Unfortunately, he defaulted his outpatient follow-up.

Our literature search yielded 12 cases of NA in patients with COVID-19 infection—8 critical and 4 mild (Supplementary Table S1 in online Supplementary Material)—and 8 after COVID-19 vaccinations—6 Pfizer-BioNTech BNT162b2, 2 Moderna mRNA-1273, and 3 after first dose (Supplementary Table S2). Both groups share similar demographics, clinical features and anatomical involvement (Table S3). Common to both groups is a greater predisposition for middle-aged males (median age 52 years in COVID-19 patients versus 49.5 years in those after recent vaccination), main clinical

manifestations of pain and weakness, and predominant involvement of the brachial plexus (Tables S1 and S2).

The median latency of NA was longer in COVID-19 patients than in those after recent vaccination (21 vs 8 days,  $P=0.02$ ) and may be explained by difficulty in confirming the diagnosis in critically ill COVID-19 patients in whom symptoms may not be apparent while intubated. Persistent shoulder pain and limb weakness after recovery from critical COVID-19 should raise suspicion of NA. Our patient had mild symptomatic COVID-19 and a short latency of 2 days. His 2-dose COVID-19 vaccination was completed about 4 months prior. The temporal relationship to COVID-19 infection and the short latency period suggested either a para-infectious mechanism or direct neuroinvasion.<sup>8</sup> Among 246 NA cases unrelated to COVID-19 infection nor vaccination, majority occurred 1–7 days after a postulated antecedent event; 65.3% of cases that followed infection similarly occurred in this time interval.<sup>9</sup> Unlike the majority with involvement of the upper/middle trunks, our patient had features suggestive of pan-brachial plexopathy.

Sensorimotor axonal involvement is commonly seen in electrodiagnostic studies in both groups.<sup>9</sup> Of those with brachial plexus involvement, COVID-19 patients appear to have a predilection for the upper/middle trunk (Table S1) while those recently immunised with COVID-19 vaccines seemed to predominantly involve the lower trunk (Table S2). In addition, 3/12 COVID-19 patients had bilateral brachial plexus involvement, while none with recent vaccination had bilateral involvement. These differences were however not significant, likely due to the small number of patients in this review and the patchy nature of brachial plexus inflammation.

MRI neurography/brachial plexus is a sensitive imaging modality to diagnose NA early, as shown by the positive imaging findings in our patient on day 3 of neurological symptoms. This is useful in patients who cannot undergo electrodiagnostic testing due to COVID-19 infection control measures; in those who present early before sufficient time has passed for denervation to appear on electrodiagnostic tests; and to exclude other musculoskeletal pathologies. MRI features may include neurogenic muscle oedema, muscle atrophy and fatty infiltration.<sup>10</sup>

Treatment outcomes were similar in both groups, regardless of corticosteroid effect. Notably, complete recovery was observed in only a minority of patients, possibly due to the short follow-up period (Table S3). As recovery is often protracted in NA, studies bearing data from longer term follow-up will be helpful.

Currently, there is no conclusive evidence of the superiority of corticosteroid use in treatment of NA.

Our study was limited by the small number of patients and incomplete outcome data. Therefore, the absence of significant differences in demographics or NA characteristics between COVID-19 patients and those with recent COVID-19 vaccination may be difficult to conclude.

NA may rarely occur early in mild COVID-19 and after recent vaccination. The presence of shoulder pain and limb weakness should prompt suspicion for NA, to perform further evaluation with early MRI and subsequent electrodiagnostic studies.

#### Availability of data and materials

All anonymised data relevant to the study in the article and Supplementary Material are available upon reasonable request.

#### REFERENCES

1. Mao L, Jin H, Wang M, et al. Neurologic Manifestations of Hospitalized Patients With Coronavirus Disease 2019 in Wuhan, China. *JAMA Neurol* 2020;77:683-90.
2. Thompson MG, Burgess JL, Naleway AL, et al. Prevention and Attenuation of Covid-19 with the BNT162b2 and mRNA-1273 Vaccines. *N Engl J Med* 2021;385:320-9.
3. Andrews N, Tessier E, Stowe J, et al. Duration of Protection against Mild and Severe Disease by Covid-19 Vaccines. *N Engl J Med* 2022;386:340-50.
4. Khadilkar SV, Khade SS. Brachial plexopathy. *Ann Indian Acad Neurol* 2013;16:12-8.
5. Koh JS, Goh Y, Tan BY, et al. Neuralgic amyotrophy following COVID-19 mRNA vaccination. *QJM* 2021;114:503-5.
6. World Health Organization. WHO COVID-19 Case definition. COVID-19: Surveillance, case investigation and epidemiological protocols, 16 December 2020. Available at: [https://www.who.int/publications/i/item/WHO-2019-nCoV-Surveillance\\_Case\\_Definition-2020.2](https://www.who.int/publications/i/item/WHO-2019-nCoV-Surveillance_Case_Definition-2020.2). Accessed on 20 December 2020.
7. Greene SK, Kulldorff M, Lewis EM, et al. Near real-time surveillance for influenza vaccine safety: proof-of-concept in the vaccine safety datalink project. *Am J Epidemiol* 2010;171:177-88.
8. Ren AL, Digby RJ, Needham EJ. Neurological update: COVID-19. *J Neurol* 2021;268:4379-87.
9. van Alfen N, van Engelen BG. The clinical spectrum of neuralgic amyotrophy in 246 cases. *Brain* 2006;129(Pt 2):438-50.
10. Scalf RE, Wenger DE, Frick MA, et al. MRI findings of 26 patients with Parsonage-Turner syndrome. *AJR Am J Roentgenol* 2007;189:W39-W44.

Gee Jin Ng <sup>\*1</sup>*MRCP*, Yi Rong Chiew <sup>\*1</sup>*MRCP*,  
Yongyao Kong <sup>1</sup>*MRCP*, Jasmine Shimin Koh <sup>1</sup>*MRCP*

<sup>1</sup> Department of Neurology, National Neuroscience Institute, Singapore

\* Joint first authors

Correspondence: Dr Gee Jin Ng, Department of Neurology, National Neuroscience Institute, 11 Jalan Tan Tock Seng, Singapore 308433.  
Email: [ng.gee.jin@singhealth.com.sg](mailto:ng.gee.jin@singhealth.com.sg)