


## CASE REPORT

# Myocarditis following COVID-19 mRNA (mRNA-1273) vaccination

Suresh Babu Chellapandian<sup>1</sup> | Suha Turkmen<sup>1,2</sup>  | Imtiaz Salim<sup>3</sup> |  
Shanmugavel Chinnakaruppan<sup>4</sup> | Jassim Mohammad<sup>3</sup>

<sup>1</sup>Department of Emergency Medicine, Hamad Medical Corporation, Doha, Qatar

<sup>2</sup>Department of Emergency Medicine, Acibadem University, Istanbul, Turkey

<sup>3</sup>Department of Cardiology Medicine, Hamad Medical Corporation, Doha, Qatar

<sup>4</sup>Department of Radiology, Hamad Medical Corporation, Doha, Qatar

**Correspondence**

Süha Türkmen, Department of Emergency Medicine, Hamad Medical Corporation, Doha, Qatar.  
Email: [drsuhaturkmen@hotmail.com](mailto:drsuhaturkmen@hotmail.com)

**Funding information**

Qatar National Library; Hamad Medical Corporation

**Abstract**

In this case report, we presented a case of myocarditis as a rare complication that developed after Covid mRNA-1273 vaccine. Cases of post-vaccine myocarditis usually progress with mild symptoms. However, it should be a situation that healthcare workers should keep in mind, that myocarditis may develop after vaccination.

**KEYWORDS**

Covid-19, mRNA-1273 vaccine, myocarditis

## 1 | INTRODUCTION

Myocarditis is an advanced inflammation of the myocardium. Immune reaction in the heart causes structural and functional abnormalities in cardiomyocytes, which can lead to contractile dysfunction or cardiac conduction disorders.<sup>1</sup> In many patients with myocarditis, the causes often accused are infectious agents, systemic diseases, drugs, toxins, and vaccine, although the exact cause cannot be shown. Smallpox, influenza, human papilloma virus vaccine, tetanus, and hepatitis B virus vaccines have been reported as the most frequently accused vaccines among the vaccines that cause myocarditis.<sup>2</sup> Vaccines developed for Covid-19 infection prevent catching Covid infection to a large extent. The developed vaccines prevent people from

getting over the infection mildly and from encountering serious complications, even if they are infected. Fever, fatigue, and muscle pains have been reported among the frequently seen side effects of vaccines developed against Covid. However, there are also few reported hematological, allergic, and cardiac complications.<sup>3</sup> Myocarditis is one of the cardiac complications. Most patients with myocarditis recover uneventfully and return to normal cardiac function. Palpitation, syncope, arrhythmia, and atrioventricular blocks can be shown among the common complications of myocarditis. Heart failure and sudden cardiac death can be observed as rare complications.<sup>2</sup> Myocarditis cases associated with Covid infection and Covid vaccine have been reported in recent months and are still being reported.<sup>4</sup> In this case report, we presented a case of

This is an open access article under the terms of the Creative Commons Attribution-NonCommercial License, which permits use, distribution and reproduction in any medium, provided the original work is properly cited and is not used for commercial purposes.

© 2022 The Authors. *Clinical Case Reports* published by John Wiley & Sons Ltd.

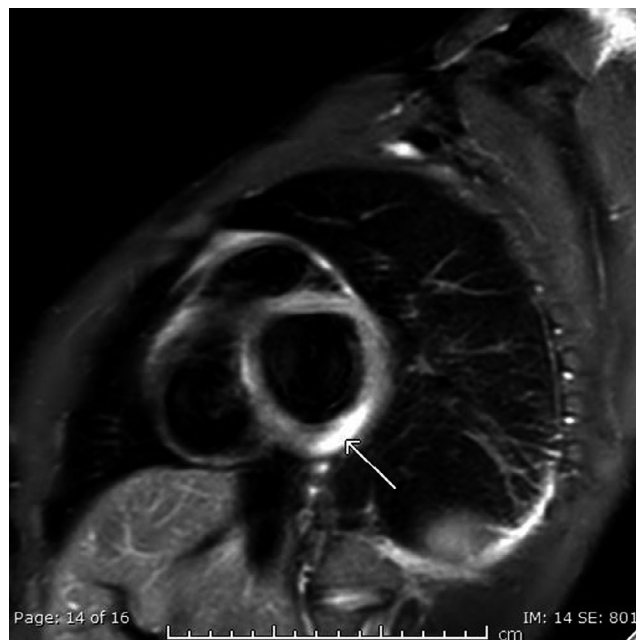
myocarditis as a rare complication that developed after the mRNA-1273 vaccine.

## 2 | CASE

A 22-year-old male patient presented to the emergency department with complaints of chest pain and generalized body pain. He described his chest pain as a central chest pain without any radiation and had been on and off for the last 2 days. There was no accompanying sweating, shortness of breath, or palpitation. This previously healthy patient did not have any risk factor for coronary artery disease. He claimed that he had his second dose of Covid vaccine 2 days before his complaints started. Patient on examination was normal and vitally stable, he was afebrile, respiratory rate was 15/min, pulse rate was 59/min, blood pressure was 115/76, and oxygen saturation was 98% on room air. The ECG showed a normal sinus rhythm, and there was no acute ST-T changes. Patient's initial blood investigations in ED showed an elevated troponin-HS value of 139, WBC was 4.400, and CRP was 6.1. Other blood values were within the normal range. No pathology was found in the echocardiography of the patient, and chest X-ray was normal. Although serial troponin-HS values increased subsequently to 169-191-263, no change was observed in ECG. The tomographic angiography images of the patient who was followed up in the intensive care unit were reported as normal. On the cardiac MRI examination, normal biventricular volume and functions were observed. Basal inferolateral myocardial edema supporting myocarditis, myocardial hyperemia, and myocardial scar were observed (Figures 1, 2, 3, and 4). The results of the patient, who underwent Covid-19 PCR test, eTreponeuma pallidum, HBV, HIV test in addition to the whole viral panel, were normal. He was started on colchicine 1 mg orally twice daily for the first day as a loading dose followed by 0.5 mg twice daily as a maintenance dose and ibuprofen 2,400 mg/day for myocarditis and the troponin levels returned back to normal within days and the patient was finally discharged.

## 3 | DISCUSSION

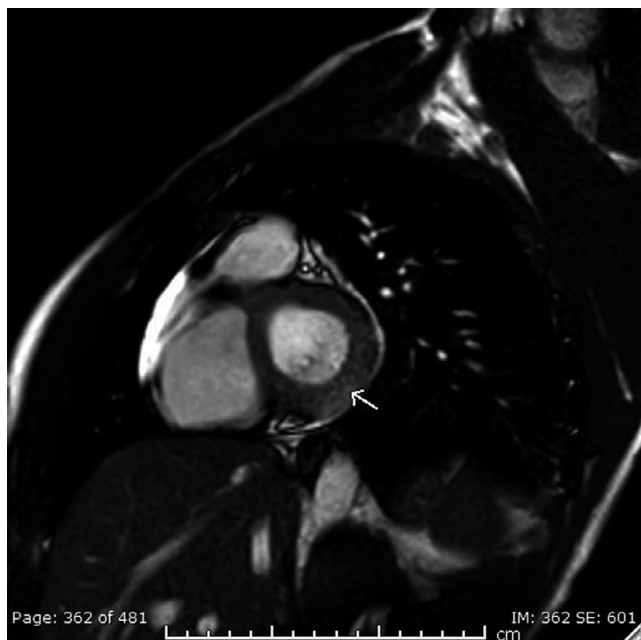
Messenger ribonucleic acid (mRNA) vaccines are vaccine types created by copying a natural molecule called mRNA to generate an immune response. Synthetic RNA that enters immune cells causes protein production such as pathogen (virus) or foreign proteins produced by cancer cells. These protein molecules stimulate the adaptive immune response and teach the body to recognize and destroy the pathogen or cancer cell. The autoimmune response



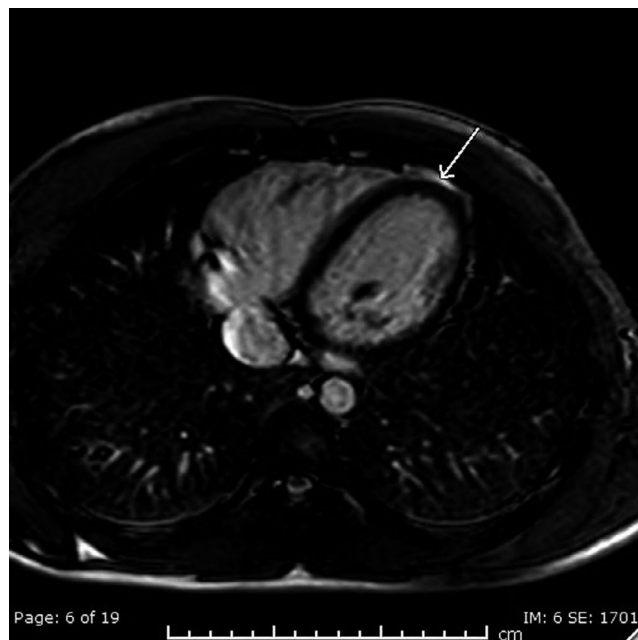
**FIGURE 1** Short axis SPIR T2 weighted image show myocardial edema in the basal inferolateral myocardium

in humans may cause side effects against RNA vaccines. Myocarditis is also thought to be a result of this autoimmune response.<sup>5</sup> Potential mechanisms for myocarditis post-mRNA-based vaccination include a nonspecific innate inflammatory response or a molecular mimicry mechanism between viral spike protein and an unknown cardiac protein.<sup>6</sup> The incidence of myocarditis is 1.5 million cases per year. A very few of these cases are seen after vaccination, and most of the myocarditis cases developed after vaccination have been reported after smallpox vaccination. It is followed by influenza vaccine, HBV vaccine, and tetanus vaccine. Most of the cases of myocarditis developing after vaccination have been reported in the elderly people.<sup>7</sup> The case we have presented is a young patient with no comorbidities.

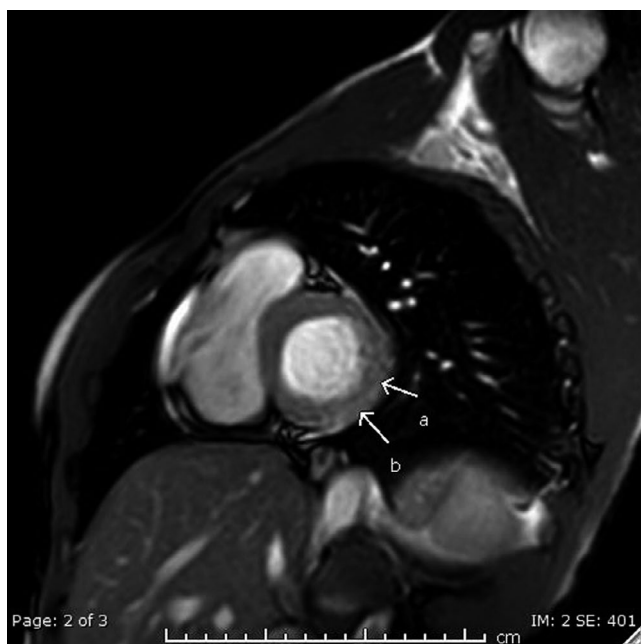
Vaccines developed in the fight against Covid infection seem to be the most important weapon at our disposal to limit this pandemic. There are vaccines that are reported to be safe and effective by WHO and developed by different methods. These vaccines have many advantages over previously developed vaccines and have far fewer side effects than those seen with previously developed vaccines. Compared with previous vaccines, mRNA vaccines can be produced faster, have lower production costs, and induce both cellular and humoral immunity.<sup>8</sup> Currently, there are two vaccines (BNT162b2 mRNA and the mRNA-1273 vaccines) developed with the mRNA technique. The efficacy of them reported to be 95%. Similar to the side effects of other vaccines, these vaccines cause side effects such as mild fever and muscle aches to a large extent. However, side



**FIGURE 2** Early arterial phase post gadolinium showing hyperemia



**FIGURE 4** Axial T2 weighted imaging show thin trace of pericardial fluid



**FIGURE 3** Late arterial phase shows patchy enhancement suggestive of myocarditis

effects such as rash and allergic reactions are also reported. Very rarely, anaphylaxis, hematologic, and cardiac complications have been reported as more serious complications.<sup>6,9</sup> As a common feature in all myocarditis cases developed as a result of the Covid vaccine, fever and muscle pains begin within 24 h after the 2nd dose and chest pain is observed within 2–4 days. In only one case, myocarditis developed after the first dose of Covid

vaccine, and this patient also had a previous Covid infection.<sup>6</sup> In our patient, fever, muscle pains, and chest pain developed within a similar period as previously reported cases. Coronary imaging was completely normal in our case, as was the case in myocarditis cases after Covid vaccine, which was reported previously, and the diagnosis of myocarditis was made with MRI.

Although there are contradictions with the treatment of myocarditis as a result of Covid vaccine, the most widely accepted treatment is corticosteroid and intravenous immunoglobulins (IVIG). Evidence-based myocarditis management guidelines of the AHA and ESC restrict the use of nonsteroidal anti-inflammatory drugs in patients with COVID-19-associated myocarditis, as they may cause renal failure and sodium retention. Myocarditis patients may also need heart failure treatment because of their hemodynamic instability and low cardiac output. Diagnostic methods should rule out fulminant myocarditis, which can cause cardiogenic shock, ventricular tachyarrhythmias, heart block, syncope, and sudden cardiac death. In the case of cardiogenic shock in patients with fulminant myocarditis, mechanical circulatory support with extracorporeal membrane oxygenation, ventricular assist device or an intra-aortic balloon pump is recommended.<sup>10</sup>

Regarding the treatment, the use of colchicine was sufficient in terms of treatment. It is in the view that the use of steroids may limit the effects of the vaccine, and the desired vaccine effect may not be possible. Therefore, it would be more appropriate to use steroid therapy for cases with fulminant myocarditis and to use it in limited doses.<sup>6</sup>

## 4 | CONCLUSION

Covid vaccine practices around the world still continues. Early detection is key to improving medical management of patients with suspected COVID-19 vaccine-associated myocarditis. Myocarditis should be a vaccine side effect that should be kept in mind by healthcare professionals. More studies are needed to better understand the cardiac complications related to the Covid vaccine.

## ACKNOWLEDGEMENT

Open Access funding provided by the Qatar National Library.

## CONFLICT OF INTEREST

None declared.

## AUTHOR CONTRIBUTIONS

Chellapandian Suresh Babu, Turkmen Suha, Salim Imtiaz, Chinnakaruppan Shanmugavel, and Mohammad Jassim; conceived and drafted the manuscript Salim Imtiaz, Chinnakaruppan Shanmugavel, and Mohammad Jassim; reviewed the literature.

## ETHICAL APPROVAL

Informed consent was obtained from the patient to publish this case report. All procedures performed in this study involving human participants were in accordance with the ethical standards of the institutional research committee and with the 1964 Helsinki declaration and its later amendments or comparable ethical standards.

## CONSENT

Written informed consent was obtained from the patient to publish this report in accordance with the journal's patient consent policy.

## DATA AVAILABILITY STATEMENT

The data that support the findings of this study are available on request from the corresponding author. The data are not publicly available due to privacy or ethical restrictions.

## ORCID

Suha Turkmen  <https://orcid.org/0000-0002-0557-6071>

## REFERENCES

1. Cooper LT Jr. Myocarditis. *N Engl J Med*. 2009;360(15):1526-1538. doi:[10.1056/nejmra0800028](https://doi.org/10.1056/nejmra0800028)
2. Caforio AL, Pankuweit S, Arbustini E, et al. Current state of knowledge on aetiology, diagnosis, management, and therapy of myocarditis: a position statement of the European society of cardiology working group on myocardial and pericardial diseases. *Eur Heart J*. 2013;34:2636-2648.
3. Albert E, Aurigemma G, Saucedo J, Gerson DS. Myocarditis following COVID-19 vaccination. *Radiol Case Rep*. 2021;16(8):2142-2145. doi:[10.1016/j.radcr.2021.05.033](https://doi.org/10.1016/j.radcr.2021.05.033)
4. Dror M, Emilia A, Noa C, et al. Myocarditis after BNT162b2 mRNA vaccine against Covid-19 in Israel. *N Engl J Med*. 2021;385(23):2140-2149.
5. Verbeke R, Lentacker I, De Smedt S, Dewitte H. Three decades of messenger RNA vaccine development. *Nano Today*. 2019;28:100766.
6. Larson KF, Ammirati E, Adler ED, et al. Myocarditis after BNT162b2 and mRNA-1273 vaccination. *Circulation*. 2021;144(6):506-508. doi:[10.1161/CIRCULATIONAHA.121.055913](https://doi.org/10.1161/CIRCULATIONAHA.121.055913)
7. Mei R, Raschi E, Forcisi E, Diemberger I, De Ponti F, Poluzzi E. Myocarditis and pericarditis after immunization: gaining insights through the vaccine adverse event reporting system. *Int J Cardiol*. 2018;15(273):183-186. doi:[10.1016/j.ijcard.2018.09.054](https://doi.org/10.1016/j.ijcard.2018.09.054)
8. Pardi N, Hogan M, Porter F, Weissman D. mRNA vaccines — A new era in vaccinology. *Nat Rev Drug Discov*. 2018;17:261-279.
9. Abu Mouch S, Roguin A, Hellou E, et al. Myocarditis following COVID-19 mRNA vaccination. *Vaccine*. 2021;39(29):3790-3793.
10. Siripanthong B, Nazarian S, Muser D, et al. Recognizing COVID-19-related myocarditis: the possible pathophysiology and proposed guideline for diagnosis and management. *Heart Rhythm*. 2020;17(9):1463-1471.

**How to cite this article:** Chellapandian SB, Turkmen S, Salim I, Chinnakaruppan S, Mohammad J. Myocarditis following COVID-19 mRNA (mRNA-1273) vaccination. *Clin Case Rep*. 2022;10:e05741. doi:[10.1002/ccr3.5741](https://doi.org/10.1002/ccr3.5741)