



IgA nephropathy after COVID-19 vaccination and analysis of reported cases

Akira Mima^{*}, Shinji Lee

Department of Nephrology, Osaka Medical and Pharmaceutical University, Osaka, Japan

ARTICLE INFO

Keywords:

IgA nephropathy
SARS-CoV-2 vaccine
COVID-19
Gross hematuria

ABSTRACT

Background: Immunoglobulin A nephropathy (IgAN) is one of the most common forms of chronic glomerulonephritis and has been shown to occur in association with vaccinations. While various vaccines against COVID-19 have become widely used, their side effects, especially on IgAN following COVID-19 vaccines are still unclear. In this report, we describe the clinical courses and histopathologic findings of a newly diagnosed case of IgAN after receiving the mRNA-1273 (Moderna) COVID-19 vaccination.

Methods: This study presents a case of new-onset IgAN following mRNA-1273 COVID-19 (Moderna) vaccination. In addition, we review and analyze similar cases previously reported in the literature up to October 2022.

Results: Of the 52 cases reviewed, including our own, the majority of patients were female, and 64% of patients had initial onset IgAN. The most common manifestation was gross hematuria (87%), other associated symptoms were fever (44%), myalgia (8%), arthralgia (4%), and edema (4%). Many of these cases occurred after receiving Pfizer products as the second vaccination. Oral corticosteroids were used to 16 cases, and steroid pulse therapy was used to treat 7 cases.

Conclusion: While this is not a controlled study, it is important for physicians to consider the possibility that COVID-19 vaccines may provoke a flare of IgAN. Several therapeutic agents may be useful for treating COVID-19 vaccine-induced IgAN, although a specific mechanism or pathophysiological association cannot be confirmed without further research.

1. Introduction

Immunoglobulin A nephropathy (IgAN) is one of the most common forms of chronic glomerulonephritis, and it has been demonstrated that IgAN can occur in association with administration of certain vaccinations or drugs [1,2]. Recently, there have been reports of initial onset and relapse of IgAN following administration of the coronavirus disease 2019 (COVID-19) vaccine as vaccination efforts continue worldwide [3,4].

Several types of vaccines are currently in use such as; BNT162b2 mRNA COVID-19 (Pfizer-BioNTech) and mRNA-1273 COVID-19 (Moderna); and vectored vaccines such as AZD1222 (Oxford-AstraZeneca) and Ad26.COV2.S (Janssen); protein subunit vaccine such as Novavax (Novavax); and inactivated vaccine such as COVID-19 vaccine Valneva (Valneva) [5,6]. Although several studies have described cases of IgAN occurring after COVID-19 vaccinations, the number of cases is limited, and the relationship between IgAN and COVID-19 vaccination has not been fully elucidated. Therefore, we present a newly diagnosed case of IgAN confirmed by kidney biopsy

^{*} Corresponding author. Department of Nephrology, Osaka Medical and Pharmaceutical University, Osaka, 569-8686, Japan.
E-mail address: akira.mima@ompu.ac.jp (A. Mima).

following the administration of the second dose of Moderna's COVID-19 vaccine and analyze 51 similar cases previously reported in the literature.

2. Methods

2.1. Case presentation

All procedures involving human participant in this study were performed in accordance with the ethical standards of the institutional and/or national research committee and with the 1964 Helsinki Declaration and its later amendments or comparable ethical standards. Written informed consent was obtained from the patient, including consent for publication of the paper. Since the number of patients in this study was less than nine, an ethical review was not required by the institutional (Osaka Medical and Pharmaceutical University) review board rules. Data were collected and analyzed retrospectively using electronic medical records maintained by the Department of Nephrology at Osaka Medical and Pharmaceutical University Hospital.

Data on age, race, sex, initial onset or relapse of IgAN after vaccination, vaccine company, dose, onset of gross hematuria after vaccination, the degree of hematuria, proteinuria, and serum creatinine before and after vaccination, other symptoms, and specific treatment for IgAN were obtained from the electronic medical records and kidney biopsy database.

2.2. Kidney biopsy

Kidney specimens were obtained using a 16-gauge biopsy needle (Bard, New Providence, NJ). Specimens were fixed in 10% formalin for the staining with Masson's trichrome, or periodic acid-Schiff stains (PAS) and fixed in 2% glutaraldehyde for electron microscopy. Pathological data were obtained from kidney biopsy database. At least three pathologists evaluated the specimens.

2.3. Literature review

We searched MEDLINE (via PubMed) and Google scholar databases to identify full-length articles from inception to October 2022,

Table 1
Clinical data on admission.

Laboratory data	
White blood cells ($10^3/\mu\text{L}$)	4.86
Hemoglobin (g/dL)	12.1
Platelet ($10^3/\mu\text{L}$)	304
Total bilirubin (mg/dL)	0.6
AST (IU/L)	16
ALT (IU/L)	8
LDH (U/L)	132
Albumin (g/dL)	4.3
BUN (mg/dL)	8
Creatinine (mg/dL)	0.57
eGFR ($\text{mL}/\text{min}/1.73\text{m}^2$)	111
Na (mEq/L)	139
K (mEq/L)	3.6
IgA (mg/dL)	280
C3 (mg/dL)	90
C4 (mg/dL)	14
ASO (IU/L)	53
MPO-ANCA (EU)	<0.5
PR3-ANCA (EU)	<0.5
Anti-ds-DNA Ab (IU/mL)	<1.2
Anti-Sm Ab (IU/mL)	<10.0
Urinalysis	
pH	5.5
Blood	3+
Protein	–
Red blood cells (hpf)	1–4
Urinary protein (g/g creatinine)	0.19

AST: aspartate aminotransferase, ALT: alanine aminotransferase, LDH: lactate dehydrogenase, BUN: blood urea nitrogen, eGFR: estimated glomerular filtration rate, Na: serum sodium, K: potassium, IgA: immunoglobulin A, C3: complement C3, C4: complement C4, ASO: anti-streptolysin O antibody, MPO-ANCA: myeloperoxidase-anti-neutrophil cytoplasmic antibodies, Anti-ds-DNA Ab: anti-double stranded DNA antibody, Anti-Sm Ab: anti-Smith antibody.

regardless of the language of publication. The following search terms were used (IgA nephropathy OR IgAN OR Immunoglobulin A nephropathy OR glomerulonephritis OR nephropathies OR hematuria) AND (COVID-19 OR SARS-CoV-2 OR 2019-nCoV OR novel corona virus OR coronavirus) AND (vaccine OR vaccination). We extracted baseline characteristics, experimental data regarding presentations and treatments.

2.4. Statistical analyses

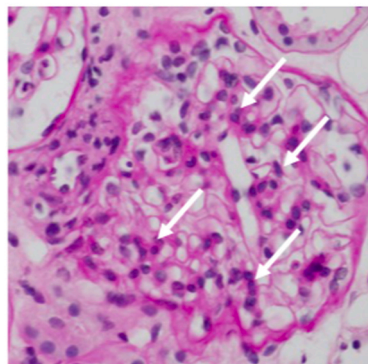
The data are expressed as mean values \pm SD. All analyses were performed using Excel software (Microsoft, Redmond, WA, USA).

3. Results

3.1. Case presentation

A 20-year-old Japanese woman presented with fever and new-onset gross hematuria 1 day after receiving the second dose of Moderna mRNA-1273 COVID-19 vaccine injection. She had no history of previous infections such as tonsilitis. She was known to have not been infected with severe acute respiratory syndrome coronavirus-2 (SARS-CoV-2) infection. After receiving first dose of the Moderna mRNA-1273 COVID-19, she experienced fever (body temperature, 38 °C). Three days after vaccination, the patient was referred and admitted to our hospital for proteinuria (2+) and occult blood (3+). On admission, the patient presented with a body temperature of 37.5 °C and blood pressure was 118/61 mmHg. The physical examination revealed normal findings of the cardiac, pulmonary, abdominal, and neurological systems. Table 1 shows the clinical data on admission. The initial urinalysis conducted upon admission revealed mild proteinuria of 0.19 g/g creatinine (urine protein-to-creatinine ratio), as well as the presence of occult blood (3+). The shape of erythrocytes appeared dysmorphic, indicating glomerular hematuria. The serum creatinine was measured at 0.57 mg/dL and estimated glomerular filtration rate (eGFR) was 111 ml/min/1.73 m². Immunoglobulin A, complement C3 and C4 were within normal range. Hepatitis B surface antigen (HBsAg) and hepatitis C antibody (HCV-Ab) tests were negative. Anti-streptolysin O antibody (ASO) was normal. Anti-neutrophil cytoplasmic myeloperoxidase anti-body (MPO-ANCA), anti-neutrophil cytoplasmic

A



B

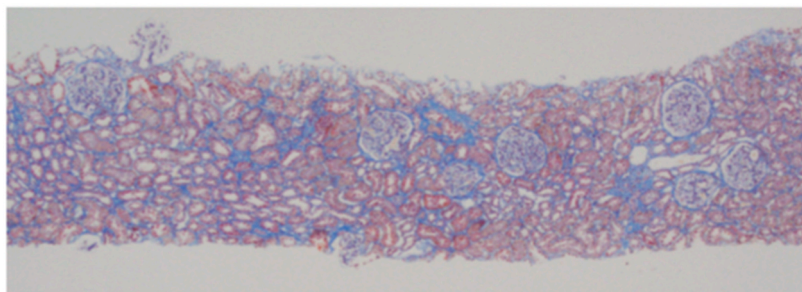


Fig. 1. Light microscopic findings of the kidney biopsy. (A) Focal mild mesangial hypercellularity was present (white arrows. Periodic acid-Schiff staining was performed. Original magnification $\times 400$). (B) Mild fibrosis in the tubulointerstitium (Masson's trichrome staining was performed. Original magnification $\times 40$).

proteinase 3 antibody (PR3-ANCA) were negative.

To confirm the glomerulonephritis, a kidney biopsy was performed. Light microscopy revealed 10 glomeruli with mild mesangial expansion and hypercellularity. Neither double contours nor spikes in the glomerular capillaries were observed. Cellular or fibro-cellular crescents, segmental sclerosis, proliferation of endocapillary cells, and subepithelial deposits were not observed (Fig. 1A). Tubular atrophy and interstitial fibrosis accounted for approximately 5–10% of the entire interstitium (Fig. 1B). Immunofluorescence showed diffuse moderate-to-intense deposits of IgA (2+) and C3 (1+) in mesangial lesions. IgG, IgM, and C1q were negative (Fig. 2A–E). Histopathological features were consistent with IgAN. Electron microscopy revealed electron-dense deposits in the mesangial and paramesangial areas (Fig. 3). The Oxford MEST-C score was classified as M1E0S0T0C0. Intravenous

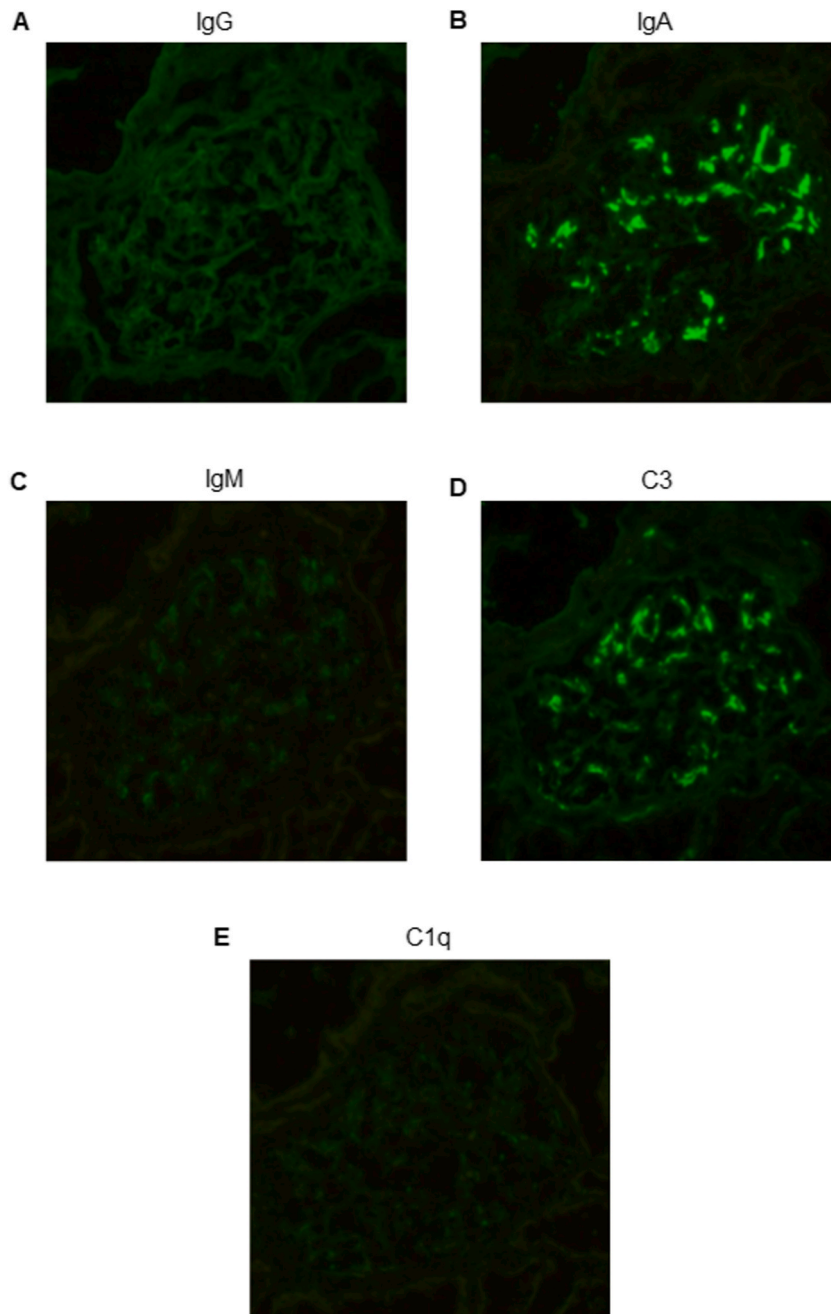


Fig. 2. Immunofluorescence staining of kidney biopsy. IgA- (2+) and C3- (1+) dominant granular diffuse global mesangial immunofluorescence (Original magnification $\times 200$). (A) IgG (B) IgA (C) IgM (D) C3 (E) C1q.

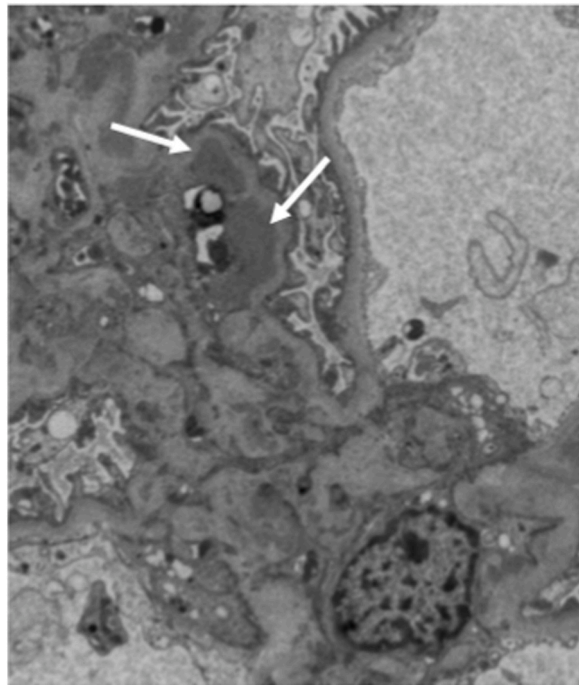


Fig. 3. Electron micrography. Electron dense deposits (white arrows) in the mesangial area (Original magnification $\times 4000$).

methylprednisolone at 500 mg for 3 days was initiated, after which oral prednisolone (30 mg/day) was given. Promptly after treatment, both urinary protein and occult blood disappeared.

3.2. Search results

Fifty-two previously reported cases of IgA nephropathy or vasculitis with renal impairment occurring post-COVID-19 vaccination are summarized in [Table 2](#), including our case.

There was no significant difference in the number of cases between female and male (female/male ratio, 0.9; mean age, 34.1 ± 17.1 years). The types of COVID-19 vaccines associated with relapse/flare or initial diagnosis of IgAN are as follows; Pfizer (28 cases), Moderna (17 cases), Oxford-AstraZeneca (4 cases), and Sinovac (1 case). Forty cases (77%) occurred after second injection of COVID-19 vaccination.

Out of the total number of cases, thirty-four were initial onset and eighteen were relapse. The time from vaccine injection to onset ranged from 1 to 35 days (mean, 3.9 ± 7.4 days), but 1–2 days was the most common. Mean proteinuria at the onset of IgAN after COVID-19 vaccination was 2.4 ± 3.4 g/day or g/g creatinine, and mean serum creatinine was 1.4 ± 0.8 mg/dL. Gross hematuria was observed in most cases (87%). Of all cases, 23 cases (44%) showed gross hematuria 1–2 days after COVID-19 vaccination. Other associated symptoms were fever (44%), myalgia (8%), arthralgia (4%), and edema (4%). Eleven of the 52 patients (21%) were untreated, while 19 cases (37%) required oral corticosteroid administration, and 6 cases (12%) were treated with steroid pulse therapy. Renin-angiotensin-aldosterone system inhibitors were administered in 16 cases (31%).

4. Discussion

4.1. Summary of the current study

In this study, we presented a case of new-onset IgAN with gross hematuria following inoculation with the Moderna vaccine against COVID-19 and reviewed the clinical course, treatment, and histopathological findings of new-onset and flare IgAN following COVID-19 vaccination. As this is not a controlled study, we cannot conclude a causal relationship between COVID-19 vaccination and IgAN. However, COVID-19 vaccination is known to be associated with new onset and recurrence of glomerular disease due to its potent immunomodulatory effects, and various therapeutic effects have been reported [[7,9,11,12,15,21,26–28,31,32,34–38,40](#)].

Table 2

Previous reported cases of IgA nephropathy and COVID-19 vaccination.

Case	Age	Race	Sex	Initial onset or relapse of IgAN after vaccination	Vaccine company	Dose	Onset of gross hematuria after vaccination	Hematuria, proteinuria and serum creatinine before vaccination	Hematuria, proteinuria and serum creatinine after onset	Other symptoms	Specific treatment for IgAN	Follow-up	Reference
Our case	20	Asian	F	Initial onset	Moderna	Second	1 day	N/A, N/A, N/A	1-4/HPF, 0.19 g/gCr, 50.4 μ mol/L	Fever	Methylprednisolone pulses followed by oral prednisone	Hematuria and proteinuria were resolved after methylprednisolone pulses.	N/A
1	38	Caucasian	F	Relapse	Moderna	Second	Within 24 h	Positive, 0.63 g/day, N/A (well preserved renal function)	N/A, 1.4 g/day, N/A (well preserved renal function)	Fever	RAASI before vaccination	Persistent microscopic hematuria and proteinuria	7
2	38	Caucasian	F	Relapse	Moderna	Second	Within 24 h	Positive, 0.43 g/day, N/A (well preserved renal function)	N/A, 0.4 g/day, N/A (serum creatinine did not increase)	Fever	Cyclophosphamide, prednisone and RAASI before vaccination	Persistent microscopic hematuria and proteinuria	7
3	25	Caucasian	F	Relapse	Moderna	Second	1 day	N/A, 1.41 g/gCr, 61.9 μ mol/L	N/A, 4.76 g/gCr, 94.6 μ mol/L	N/A	Supportive care (details unknown)	In 3 weeks, serum creatinine and proteinuria returned to baseline.	8
4	35	Caucasian	M	Initial onset	Moderna	Second	2 days	N/A, N/A, N/A	N/A, 0.656 g/gCr, 114.9 μ mol/L	N/A	Mycophenolate mofetil	Stable creatinine and proteinuria after 4 weeks on mycophenolate mofetil	8
5	30	Western European and South American	M	Initial onset	Moderna	Second	1 day	N/A, N/A, N/A	3+ hematuria by dipstick test, 4+ proteinuria by dipstick test, 90.2 μ mol/L	Fever	RAASI	After 6 weeks of therapy, proteinuria improved to 0.43 g/gCr and creatinine remained stable at 91.1 μ mol/L.	4
6	47	Asian	M	Initial onset (IgAV)	Moderna	Second	N/A	N/A, N/A, N/A	50-99/HPF, 2.98 g/gCr, 109.6 μ mol/L	Purpuric eruption	Methylprednisolone pulses followed by oral prednisone	After treatment, kidney function and proteinuria showed remarkable improvements.	9
7	22	N/A	M	Relapse (IgAV)	Moderna	First, Second	2 and 25 days after the first dose and 2 days after second dose	N/A, 0.2 g/gCr, N/A	N/A, 0.34 g/gCr, GFR 107 ml/min/1.73m ²	Arthralgia	Steroids for 6 months followed by RAASI	Hematuria; 0-3/HPF, proteinuria; 0.80 g/gCr, serum creatinine; 23.9 μ mol/L (Follow-up 1 month post second dose)	10
8	50	N/A	M	Initial onset	Moderna	Second	1 day	11-25/HPF, 2.40 g/gCr, 103.4 μ mol/L	>50/HPF, 3.56 g/gCr, 136.1 μ mol/L	N/A	RAASI	Hematuria; 11-25/HPF, proteinuria; 1.24 g/gCr, serum creatinine; 194.5 μ mol/L (Follow-up 1 month post second dose)	10
9	67	N/A	M	Initial onset (IgAV)	Moderna	First	1 month	0-3/HPF, 0.05 g/gCr, 106.1 μ mol/L	>50/HPF, 2.10 g/gCr, 256.4 μ mol/L	N/A	Steroid	Hematuria; 0-3/HPF, proteinuria; 1.40 g/gCr, serum creatinine; 79.6 μ mol/L (Follow-up 1 month post second dose)	10
10	42	N/A	F	Initial onset	Moderna	Second	1 day	N/A, N/A, N/A	N/A, 1.67 g/day, 41.5 μ mol/L	N/A	RAASI	Proteinuria decreased to 0.7 g/gCr.	11

(continued on next page)

Table 2 (continued)

Case	Age	Race	Sex	Initial onset or relapse of IgAN after vaccination	Vaccine company	Dose	Onset of gross hematuria after vaccination	Hematuria, proteinuria and serum creatinine before vaccination	Hematuria, proteinuria and serum creatinine after onset	Other symptoms	Specific treatment for IgAN	Follow-up	Reference
11	39	N/A	M	Initial onset	Moderna	First	N/A	N/A, N/A, N/A	N/A, N/A, N/A	Fever	Glucocorticoids, cyclophosphamide	Over the following weeks, serum creatinine normalized and proteinuria significantly decreased, but microhematuria persisted.	12
12	36	N/A	F	Relapse	Moderna	Second	Within 24 h	N/A, 0.7 g/day, 79.6 μ mol/L	363/ μ L, 203 g/mol (albumin), 159.1 μ mol/L	Fever, malaise	Prednisolone dose was increased to 0.5 mg/kg/body weight, mycophenolate mofetil	Two months later, creatinine decreased to 97.2 μ mol/L and proteinuria decreased under 0.5 g/day.	13
13	50	White	F	Initial onset	Moderna	Second	2 days	10-20/HPF, 1.3 g/gCr, 114.9 μ mol/L	>50/HPF, 2 g/gCr, 150.3 μ mol/L	Fever, generalized body aches	N/A	Gross hematuria resolved within 5 days.	14
14	19	White	M	Initial onset	Moderna	Second	2 days	N/A, N/A, N/A	Numerous red blood cells, no proteinuria, 106.1 μ mol/L	N/A	N/A	Gross hematuria resolved within 2 days.	14
15	55	N/A	M	Initial onset	Moderna	First	N/A	N/A, N/A, N/A	N/A, 11.57 g/day, 106.1 μ mol/L	Nausea, vomiting, malaise	N/A	After three months, creatinine decreased to 353.6 μ mol/L, but proteinuria persists.	15
16	54	Caucasian	F	Relapse	Moderna	Second	2 days	15/HPF, 1.03 g/gCr, 106.1 μ mol/L	50/HPF, 0.67 g/gCr, 268.7 μ mol/L	Lower extremity edema	Oral prednisone	After three months, creatinine decreased to 94.6 μ mol/L.	16
17	52	Asian	F	Relapse	Pfizer	Second	Within 24 h	N/A, 0.63 g/gCr (albumin), 61.9–70.7 μ mol/L	Resolved, 1.4 g/gCr (albumin), N/A	Fever	RAASI	Resolution of hematuria and improving proteinuria	17
18	41	Asian	F	Relapse (unmasked)?	Pfizer	Second	Within 24 h	N/A, negative, N/A	>200/HPF, 2.03 g/gCr, 135.3 μ mol/L	Myalgia	N/A	N/A	3
19	N/A	N/A	N/A	Relapse	Pfizer	Second	6 days	N/A, 1.56 g/gCr, 70.7 μ mol/L	Positive, 4.97 g/gCr, 312 μ mol/L	Fever, chill, body ache, dysuria	Prednisone and RAASI before vaccination	Recovery to baseline renal function at 1 month and recovery to baseline proteinuria within 2 months	18
20	N/A	N/A	N/A	Relapse	Pfizer	Second	1 day	N/A, 0.61 g/gCr, 88.4 μ mol/L	Positive, 0.92 g/gCr, 102.5 μ mol/L	Body ache	RAASI	N/A	18
21	41	N/A	F	Relapse	Pfizer	First	2 days	N/A, negative, N/A	N/A, 0.47 g/gCr, GFR 57 ml/min/1.73m ²	Marked leukocytosis	Tacrolimus, mycophenolic acid, and steroid for kidney transplantation	N/A	19
22	22	N/A	F	Relapse	Pfizer	First Second	2 days after the second dose	4-10/HPF, negative, 70.7 μ mol/L	>50/HPF, 0.4 g/gCr, 70.7 μ mol/L	Abdominal pain, urticaria, moderate pancytopenia	None	Hematuria; 0–3/HPF, proteinuria; 0.27 g/gCr, serum creatinine; 70.7	10

(continued on next page)

Table 2 (continued)

Case	Age	Race	Sex	Initial onset or relapse of IgAN after vaccination	Vaccine company	Dose	Onset of gross hematuria after vaccination	Hematuria, proteinuria and serum creatinine before vaccination	Hematuria, proteinuria and serum creatinine after onset	Other symptoms	Specific treatment for IgAN	Follow-up	Reference
23	21	Asian	F	Initial onset	Pfizer	Second	2 days	3+ hematuria by dipstick test, negative, 53 $\mu\text{mol/L}$	>100/HPF, 0.15 g/gCr, 50.4 $\mu\text{mol/L}$	Fever	None	$\mu\text{mol/L}$ (Follow-up 1 month post second dose) Hematuria; 10–19/HPF, proteinuria; 0.09 g/gCr, serum creatinine; 49.5 $\mu\text{mol/L}$ (Follow-up 6 weeks post second dose)	20
24	Early 40s	Asian	F	Initial onset	Pfizer	First	9 days	N/A, 1+ proteinuria by dip stick, 67.2 $\mu\text{mol/L}$	3+, 18.1 g/gCr, 108.7 $\mu\text{mol/L}$	Fever, chill, back pain, general malaise, thrombopenia	None	Two months after discharge, the serum creatinine level and proteinuria decreased to almost normal levels, while the microscopic hematuria persisted.	21
25	17	Asian	F	Initial onset	Pfizer	First	4 days	20-29/HPF, N/A, N/A	N/A, 0.37 g/gCr, 51.3 $\mu\text{mol/L}$	N/A	None	Hematuria; 30–49/HPF, proteinuria; 0.07 g/gCr (Follow-up 16 days post second dose)	22
26	28	N/A	F	Initial onset	Pfizer	Second	N/A	N/A, 0.23 g/gCr, 58.3 $\mu\text{mol/L}$	N/A, 28 g/gCr, 71.6 $\mu\text{mol/L}$	N/A	N/A	Three weeks later, proteinuria decreased to 0.38 g/gCr.	23
27	58	N/A	F	Initial onset?	Pfizer	Second	1 day	N/A, 0.27 g/gCr, N/A (well preserved renal function)	N/A, N/A, 77.8 $\mu\text{mol/L}$	N/A	None	Three weeks later, creatinine level remained stable at 77.8 $\mu\text{mol/L}$.	23
28	28	Asian	F	Initial onset	Pfizer	Second	7 days	N/A, N/A, N/A	>100/HPF, 0.13 g/gCr, 61.9 $\mu\text{mol/L}$	Fever, headache	None	Hematuria and mild proteinuria gradually improved to within the normal range.	24
29	29	N/A	F	Initial onset?	Pfizer	First	2 days	N/A, N/A, N/A	5-10, 0.06 g/gCr (albumin), 69 $\mu\text{mol/L}$	Fever, myalgia	None	N/A	25
30	13	N/A	F	Initial onset	Pfizer	First	Within 24 h	N/A, N/A, N/A	N/A, 3.88 g/L, 315.6 $\mu\text{mol/L}$	Fever, asthenia, muscle pain	Methylprednisolone pulses followed by oral prednisone	At 30 days post-vaccination, serum creatinine had returned to almost normal values (76 $\mu\text{mol/L}$). Microscopic hematuria and a slight proteinuria persisted.	26
31	17	Asian	M	Initial onset	Pfizer	Second	2 days	2+ hematuria by dipstick test, N/A, N/A	>100/HPF, 1.0 g/gCr, 61.9 $\mu\text{mol/L}$	Fever, headache	Steroid pulse, tonsillectomy	N/A	27
32	13	Caucasian	M	Relapse	Pfizer	Second	Within 24 h	N/A, 1.6 g/gCr, 47.7 $\mu\text{mol/L}$	N/A, 1.07 g/gCr, 115.8 $\mu\text{mol/L}$	Vomiting	RAASI	Within 1 week, gross hematuria self-resolved, and kidney function recovered (proteinuria; 0.86 g/gCr,	28

(continued on next page)

Table 2 (continued)

Case	Age	Race	Sex	Initial onset or relapse of IgAN after vaccination	Vaccine company	Dose	Onset of gross hematuria after vaccination	Hematuria, proteinuria and serum creatinine before vaccination	Hematuria, proteinuria and serum creatinine after onset	Other symptoms	Specific treatment for IgAN	Follow-up	Reference
33	17	Caucasian	M	Initial onset	Pfizer	Second	Within 24 h	N/A, N/A, N/A	N/A, 1.75 g/gCr, 157.4 μ mol/L	None	Methylprednisolone pulses followed by oral prednisone	serum creatinine; 58.3 μ mol/L). Creatinine decreased to 106.1 μ mol/L.	28
34	46	Asian	F	Relapse	Pfizer	Second	After 12 h	<5/HPF, N/A, 46 μ mol/L	>100/HPF, 3+ proteinuria by dipstick test, 48.6 μ mol/L	Fever, myalgia	N/A	N/A	29
35	15	Asian	F	Relapse	Pfizer	Second	2 days	N/A, N/A, N/A	N/A, mild proteinuria, N/A	N/A	None	N/A	30
36	16	Asian	F	Relapse	Pfizer	Second	3 days	N/A, 0.5–1.0 g/gCr, N/A	After 5 days later, serum creatinine level did not increase. Bland urine, 2 g/gCr, 99.9 μ mol/L	Fever, headache	None	Urinalysis results normalized.	30
37	35	N/A	F	Relapse	Pfizer	Second	N/A	N/A, 0.36 g/gCr, 88.4 μ mol/L	N/A, 1.75 g/gCr, 99.9 μ mol/L	N/A	Oral prednisolone, Mycophenolate Mofetil	Four weeks later, proteinuria decreased to 1.143 mg/gCr and serum creatinine remained stable at 97.2 μ mol/L	31
38	50	N/A	M	Initial onset	Pfizer	First	None	Negative hematuria by dipstick test, negative proteinuria by dipstick test, 79.6 μ mol/L	10/HPF, 2+ proteinuria by dipstick test, 79.6 μ mol/L	Purpuric rashes	RAASI	After 100 days first vaccination, proteinuria decreased to 0.5 g/day.	32
39	50	N/A	M	Relapse	Pfizer	First	3 days	N/A, 0.7 g/day, 88.4 μ mol/L	170/ μ L, 329 g/mol (albumin), 106.1 μ mol/L	N/A	N/A	N/A	13
40	15	Asian	M	Initial onset	Pfizer	Second	1 day	N/A, N/A, N/A	3+ hematuria by dipstick test, 3+ proteinuria by dipstick test, 85.7 μ mol/L	Fever	None	Microscopic hematuria and proteinuria persisted.	33
41	18	Asian	M	Initial onset	Pfizer	Second	2 days	N/A, N/A, N/A	3+ hematuria by dipstick test, 1+ proteinuria by dipstick test, 72.5 μ mol/L	Fever	None	Microscopic hematuria and proteinuria disappeared gradually.	33
42	12	N/A	M	Initial onset	Pfizer	First	Within 24 h	N/A, N/A, N/A	Gross hematuria, 1.7	Fever	Methylprednisolone pulses followed by oral prednisone	N/A	34

(continued on next page)

Table 2 (continued)

Case	Age	Race	Sex	Initial onset or relapse of IgAN after vaccination	Vaccine company	Dose	Onset of gross hematuria after vaccination	Hematuria, proteinuria and serum creatinine before vaccination	Hematuria, proteinuria and serum creatinine after onset	Other symptoms	Specific treatment for IgAN	Follow-up	Reference
43	26	Asian	M	Initial onset	Pfizer	Second	1 day	N/A, 74 mg/ mmol, 75.1 μmol/L	g/L, 156.5 μmol/L >100/HPF, 174 mg/mmol, 143.2 μmol/L	Fever	RAASI, omega-3 fish oil	Normal albuminuria and renal function	35
44	12	N/A	M	Initial onset	Pfizer	Second	2 days	N/A, 1.4 g/gCr, 150.3 μmol/L	>60/HPF, 2.9 g/gCr, 70.7 μmol/L	None	Glucocorticoid, RAASI	Hematuria; negative, proteinuria; 0.1 g/gCr (Follow-up 4 months after discharge)	36
45	45	N/A	M	Initial onset	AstraZeneca	Second	N/A	N/A, N/A, N/A	8-10/HPF, 1.75 g/gCr, N/A	Purpuric rashes, polyarthralgia	Glucocorticoid	Normal albuminuria and normal renal function	37
46	30	N/A	M	Initial onset	AstraZeneca	Second	None	N/A, N/A, N/A	10-15/HPF, 2.23 g/gCr, N/A	Purpuric rashes, polyarthralgia	Prednisolone, RAASI	Normal proteinuria 2 months after stopping the drugs	37
47	73	N/A	M	Initial onset	AstraZeneca	Second	5 weeks	Negative, 0.25 g/day, GFR 43 ml/min/1.73 m ²	5-10/HPF, 1.9 g/day, GFR; 35 ml/min/1.73 m ²	None	RAASI	N/A	38
48	73	N/A	M	Initial onset	AstraZeneca	Second	N/A	None, 0.25 g/ day, GFR-CKD- EPI; 43 ml/ min/1.73 m ²	5-10, 1.9 g/day, GFR-CKD-EPI; 35 ml/min/ 1.73 m ²	Edema of the lower legs	RAASI		38
49	58	N/A	M	Initial onset	Sinovac	First	2 days	N/A, N/A, N/A	3+ hematuria by dipstick test, 1.69 g/day, 106.1 μmol/L	Body aches, dizziness	Intravenous methylprednisolone	Renal function deteriorated further to the point that he underwent dialysis.	39
50	16	Asian	M	Initial onset	N/A	Second	Within 24 h	50-100/HPF, 0.03 g/gCr, 76.9 μmol/L	Gross hematuria, 0.28 g/gCr, 97.2 μmol/L	Fever	Methylprednisolone pulses followed by oral prednisone	After 3 months vaccination, creatinine decreased to 92.8 μmol/L.	40
51	13	Asian	M	Initial onset	N/A	Second	Within 24 h	10-20/HPF, 0.08 g/gCr, 45.1 μmol/L	Gross hematuria, 1.99 g/gCr, 47.7 μmol/L	Fever	None	After 26 days, proteinuria decreased.	40

IgAN; IgA nephropathy, IgAV; IgA vasculitis, F; female, M; male, N/A; not applicable, RAASI; renin angiotensin aldosterone system inhibitors, g/gCr; urine protein-to-creatinine ratio, GFR; glomerular filtration rate, HPF; high power field, CKD-EPI; Chronic Kidney Disease Epidemiology Collaboration.

4.2. mRNA-COVID-19 vaccination-induced IgAN

Moderna COVID-19 vaccine (mRNA-1273) is a novel messenger RNA vaccine that contains nucleoside-modified RNA encoding a membrane-anchored full-length SARS-CoV-2 spike protein and a two-point protein substitution that preferentially locks the protein into its antigenic structure. It has demonstrated a high efficacy rate with acceptable adverse effects [41]. However, a possible association between mRNA-COVID-19 vaccine and IgAN has been reported [3,4,17,42]. Some patients have reported gross hematuria after receiving mRNA-COVID-19 vaccination [8,10,14,16,18–20,22,23,25,29,30,33,39]. However, it is unclear whether the gross hematuria is due to a flare-up of IgAN itself or to the development of other types of glomerulonephritis associated with mRNA vaccines.

4.3. IL-6-mediated IgAN

Several possible mechanisms have been proposed for the development of IgAN due to COVID-19 infection. It is thought that the infection of mucosal surfaces promotes the production of interleukin (IL)-6, leading to abnormalities in the glycosylation of IgA1 and an increase in galactose-deficient IgA1, which can deposit immune complexes on mesangial membranes and lead to glomerulonephritis [43]. IL-6 has also been shown to be elevated in the glomeruli of individuals with chronic kidney disease, which suggests that IL-6-mediated IgAN relapse may be higher in the presence of pre-existing IgAN [13,44–46].

4.4. Association between COVID-19 vaccine and IgA1 anti-glycan immune response

The rapid onset of gross hematuria immediately after the second dose of the COVID-19 vaccine suggests a systemic cytokine-induced flare, probably via an enhanced IgA1 anti-glycan immune response [47,24]. Therefore, the expression of de novo antibodies may lead to the deposition of immune complexes containing IgA and the development of new-onset IgAN. On the other hand, IgAN relapse after the second dose of COVID-19 vaccine without a history of exposure to SARS-CoV-2 has been attributed to a delayed hypersensitivity reaction mediated by a cell-mediated immune response [17,18]. Previous studies have shown that deficiency of galactose in the O-linked glycan of the hinge region (Gd-IgA1) can be detected in the glomerular mesangial region of the kidney in IgAN [47]. Interestingly, the urine Gd-IgA1 level was highest at the onset of gross hematuria after mRNA-COVID-19 vaccination [24]. One possible mechanism is that stimulation of Toll-like receptors by mRNA-COVID-19 vaccination may affect the production of Gd-IgA1 [48,49]. However, the exact mechanism by which mRNA vaccines induce IgAN is still unclear, and further studies will be required to elucidate it.

5. Conclusion

In summary, mRNA-COVID-19 vaccination has been associated with relapse or new diagnosis of IgAN, but the exact relationship between the two is not fully understood. Physicians should be aware of possibility of flare in patients with IgAN who have recently received mRNA-COVID-19 vaccination.

Author contribution statement

Akira Mima: Conceived and designed the experiments; Performed the experiments; Analyzed and interpreted the data; Wrote the paper.

Shinji Lee: Performed the experiments; Analyzed and interpreted the data.

Funding statement

This work was supported by JSPS KAKENHI Grant Number 22K08368 (to Akira Mima).

Data availability statement

Data will be made available on request.

Declaration of competing interest

Akira Mima received a speaker's honorarium from Novartis, Kyowa Kirin, Mitsubishi Tanabe, Torii, Kowa, Bayer, Eli Lilly, Mochida, Astellas, and Boehringer Ingelheim. Akira Mima received research grants from Kyowa Kirin, Sumitomo Pharma, Otsuka, Torii, Mochida, Kowa, Mitsubishi Tanabe, and Boehringer Ingelheim.

Acknowledgments

The author thanks Dr. Tatsuhiko Mori (Osaka Medical and Pharmaceutical University) for the discussions on the statistical analysis and renal pathology. Parts of this manuscript were prepared for presentation at the regional meeting of Japanese society of internal medicine.

References

- [1] A. McNally, D. McGregor, M. Searle, J. Irvine, N. Cross, Henoch-Schönlein purpura in a renal transplant recipient with prior IgA nephropathy following influenza vaccination, *Clin. Kidney J.* 6 (2013) 313–315.
- [2] A.S. Fischer, B.K. Moller, S. Krag, B. Jespersen, Influenza virus vaccination and kidney graft rejection: causality or coincidence, *Clin. Kidney J.* 8 (2015) 325–328.
- [3] H.Z. Tan, R.Y. Tan, J.C.J. Choo, C.C. Lim, C.S. Tan, A.H.L. Loh, et al., Is COVID-19 vaccination unmasking glomerulonephritis? *Kidney Int.* 100 (2021) 469–471.
- [4] M. Abramson, S. Mon-Wei Yu, K.N. Campbell, M. Chung, F. Salem, IgA nephropathy after SARS-CoV-2 vaccination, *Kidney Med.* 3 (2021) 860–863.
- [5] L.A. Jackson, E.J. Anderson, N.G. Rouphael, P.C. Roberts, M. Makhene, R.N. Coler, et al., An mRNA vaccine against SARS-CoV-2 - preliminary report, *N. Engl. J. Med.* 383 (2020) 1920–1931.
- [6] I. Acosta-Coley, L. Cervantes-Ceballos, L. Tejeda-Benitez, L. Sierra-Marquez, M. Cabarcas-Montalvo, M. Garcia-Espineira, et al., Vaccines platforms and COVID-19: what you need to know, *Trop. Dis. Travel. Med. Vaccines* 8 (2022) 20.
- [7] L. Negrea, B.H. Rovin, Gross hematuria following vaccination for severe acute respiratory syndrome coronavirus 2 in 2 patients with IgA nephropathy, *Kidney Int.* 99 (2021) 1487.
- [8] V. Srinivasan, A.S. Geara, S. Han, J.J. Hogan, G. Coppock, Need for symptom monitoring in IgA nephropathy patients post COVID-19 vaccination, *Clin. Nephrol.* 97 (2022) 193–194.
- [9] S. Nakatani, K. Mori, F. Morioka, C. Hirata, A. Tsuda, H. Uedono, et al., New-onset kidney biopsy-proven IgA vasculitis after receiving mRNA-1273 COVID-19 vaccine: case report, *CEN Case Rep.* 11 (2022) 358–362.
- [10] K. Park, S. Miyake, C. Tai, M. Tseng, N.K. Andeen, V.L. Kung, Letter regarding: “A case of gross hematuria and IgA nephropathy flare-up following SARS-CoV-2 vaccination”, *Kidney Int. Rep.* 6 (2021) 2246–2247.
- [11] J.H. Lim, M.S. Kim, Y.J. Kim, M.H. Han, H.Y. Jung, J.Y. Choi, et al., New-onset kidney diseases after COVID-19 vaccination: a case series, *Vaccines* vol. 10 (2022).
- [12] M.A. Anderegg, M. Liu, C. Saganas, M. Montani, B. Vogt, U. Huynh-Do, et al., De novo vasculitis after mRNA-1273 (Moderna) vaccination, *Kidney Int.* 100 (2021) 474–476.
- [13] L. Martinez Valenzuela, L. Oliveras, M. Goma, E. Quiros, P. Anton-Pampols, F. Gomez-Preciado, et al., Th1 cytokines signature in 2 cases of IgA nephropathy flare after mRNA-based SARS-CoV-2 vaccine: exploring the pathophysiology, *Nephron* 146 (2022) 564–572.
- [14] S. Kudose, P. Friedmann, O. Albajrami, V.D. D’Agati, Histologic correlates of gross hematuria following Moderna COVID-19 vaccine in patients with IgA nephropathy, *Kidney Int.* 100 (2021) 468–469.
- [15] Y.S. Chen, C.W. Yang, C.C. Tsai, M.D. Ang, S.F. Chou, W.C. Chiang, et al., Newly-diagnosed immunoglobulin A nephropathy with increased plasma galactose-deficient-IgA(1) antibody associated with mRNA COVID-19 vaccination: a case report, *J. Int. Med. Res.* 50 (2022), 3000605221129674.
- [16] S. Watanabe, S. Zheng, A. Rashidi, IgA nephropathy relapse following COVID-19 vaccination treated with corticosteroid therapy: case report, *BMC Nephrol.* 23 (2022) 135.
- [17] S.E.G. Rahim, J.T. Lin, J.C. Wang, A case of gross hematuria and IgA nephropathy flare-up following SARS-CoV-2 vaccination, *Kidney Int.* 100 (2021) 238.
- [18] R. Plasse, R. Nee, S. Gao, S. Olson, Acute kidney injury with gross hematuria and IgA nephropathy after COVID-19 vaccination, *Kidney Int.* 100 (2021) 944–945.
- [19] P. Perrin, X. Bassand, I. Benotmane, N. Bouvier, Gross hematuria following SARS-CoV-2 vaccination in patients with IgA nephropathy, *Kidney Int.* 100 (2021) 466–468.
- [20] H. Kanamori, Gross hematuria can be an impact of severe acute respiratory syndrome coronavirus 2 vaccination on immunoglobulin A nephropathy: a case report, *J. Med. Case Rep.* 16 (2022) 273.
- [21] Y. Fujita, K. Yoshida, D. Ichikawa, Y. Shibagaki, M. Yazawa, Abrupt worsening of occult IgA nephropathy after the first dose of SARS-CoV-2 vaccination, *CEN Case Rep.* 11 (2022) 302–308.
- [22] M. Okada, E. Kikuchi, M. Nagasawa, A. Oshiba, M. Shimoda, An adolescent girl diagnosed with IgA nephropathy following the first dose of the COVID-19 vaccine, *CEN Case Rep.* 11 (2022) 376–379.
- [23] W.K. Lo, K.W. Chan, Gross haematuria after mRNA COVID-19 vaccination in two patients with histological and clinical diagnosis of IgA nephropathy, *Nephrology* 27 (2022) 110–111.
- [24] Y. Nihei, M. Kishi, H. Suzuki, A. Koizumi, M. Yoshida, S. Hamaguchi, et al., IgA nephropathy with gross hematuria following COVID-19 mRNA vaccination, *Intern. Med.* 61 (2022) 1033–1037.
- [25] P. Diez Arias, A. Fernandez Ramos, P. Ruano, C. Sanchez, B. Quiroga, Hematuria after COVID-19 vaccination: a case report, *Clin. Nephrol.* 97 (2022) 252–254.
- [26] O. Niel, C. Florescu, IgA nephropathy presenting as rapidly progressive glomerulonephritis following first dose of COVID-19 vaccine, *Pediatr. Nephrol.* 37 (2022) 461–462.
- [27] T. Horino, D. Sawamura, S. Inotani, M. Ishihara, M. Komori, O. Ichii, Newly diagnosed IgA nephropathy with gross haematuria following COVID-19 vaccination, *QJM* 115 (2022) 28–29.
- [28] C. Hanna, L.P. Herrera Hernandez, L. Bu, S. Kizilbash, L. Najera, M.N. Rheault, et al., IgA nephropathy presenting as macroscopic hematuria in 2 pediatric patients after receiving the Pfizer COVID-19 vaccine, *Kidney Int.* 100 (2021) 705–706.
- [29] T. Horino, IgA nephropathy flare-up following SARS-CoV-2 vaccination, *QJM* 114 (2021) 735–736.
- [30] T. Udagawa, Y. Motoyoshi, Macroscopic hematuria in two children with IgA nephropathy remission following Pfizer COVID-19 vaccination, *Pediatr. Nephrol.* 37 (2022) 1693–1694.
- [31] T. Schaubsluger, N. Rajora, S. Diep, T. Kirtke, Q. Cai, A.R. Hendricks, et al., De novo or recurrent glomerulonephritis and acute tubulointerstitial nephritis after COVID-19 vaccination: a report of six cases from a single center, *Clin. Nephrol.* 97 (2022) 289–297.
- [32] M.M.B. Mohamed, T.J. Wickman, A.B. Fogo, J.C.Q. Velez, De novo immunoglobulin A vasculitis following exposure to SARS-CoV-2 immunization, *Ochsner J.* 21 (2021) 395–401.
- [33] Y. Uchiyama, H. Fukasawa, Y. Ishino, D. Nakagami, M. Kaneko, H. Yasuda, et al., Sibling cases of gross hematuria and newly diagnosed IgA nephropathy following SARS-CoV-2 vaccination, *BMC Nephrol.* 23 (2022) 216.
- [34] D.H. Abdel-Qader, I. Hazza Alkhatatbeh, W. Hayajneh, H. Annab, A.Z. Al Meslamani, R.A. Elmusa, IgA nephropathy in a pediatric patient after receiving the first dose of Pfizer-BioNTech COVID-19 vaccine, *Vaccine* 40 (2022) 2528–2530.
- [35] L.C. Leong, W.Z. Hong, P. Khatri, Reactivation of minimal change disease and IgA nephropathy after COVID-19 vaccination, *Clin. Kidney J.* 15 (2022) 569–570.
- [36] D.Y. Kim, H.E. Yim, M.H. Son, YooKH, Newly diagnosed pediatric immunoglobulin A nephropathy after vaccination against SARS-CoV-2: a case report, *Child Kidney Dis.* 26 (2022) 91–96.
- [37] V.K. Jha, R.S. Akai, D. Mahapatra, S. Harikrishnan, G.K. Walia, Two cases of adult-onset de novo immunoglobulin A vasculitis with nephritis: post-Covishield (ChAdOx1 nCoV-19; Oxford–Astra Zeneca) vaccination, *Indian J. Rheumatol.* 17 (2022) 294–299.
- [38] M. Mokos, N. Basic-Jukic, IgA nephropathy following SARS-CoV-2 vaccination in a renal transplant recipient with a history of aristolochic acid nephropathy, *Ther. Apher. Dial.* 26 (2022) 667–668.
- [39] E. Ran, M. Wang, Y. Wang, R. Liu, Y. Yi, Y. Liu, New-onset crescent IgA nephropathy following the CoronaVac vaccine: a case report, *Medicine (Baltim.)* 101 (2022), e30066.
- [40] K. Morisawa, M. Honda, Two patients presenting IgA nephropathy after COVID-19 vaccination during a follow-up for asymptomatic hematuria, *Pediatr. Nephrol.* 37 (2022) 1695–1696.
- [41] E. Fang, X. Liu, M. Li, Z. Zhang, L. Song, B. Zhu, et al., Advances in COVID-19 mRNA vaccine development, *Signal Transduct. Targeted Ther.* 7 (2022) 94.
- [42] Y. Ma, G. Xu, New-onset IgA nephropathy following COVID-19 vaccination, *QJM* 116 (2023) 26–39.
- [43] M.H. Heineke, A.V. Ballering, A. Jamin, S. Ben Mkaddem, R.C. Monteiro, M. Van Egmond, New insights in the pathogenesis of immunoglobulin A vasculitis (Henoch-Schönlein purpura), *Autoimmun. Rev.* 16 (2017) 1246–1253.

- [44] A. Mima, J. Hiraoka-Yamamoto, Q. Li, M. Kitada, C. Li, P. Gerald, et al., Protective effects of GLP-1 on glomerular endothelium and its inhibition by PKC β activation in diabetes, *Diabetes* 61 (2012) 2967–2979.
- [45] A. Mima, Inflammation and oxidative stress in diabetic nephropathy: new insights on its inhibition as new therapeutic targets, *J. Diabetes Res.* 2013 (2013), 248563.
- [46] A. Mima, T. Yasuzawa, G.L. King, S. Ueshima, Obesity-associated glomerular inflammation increases albuminuria without renal histological changes, *FEBS Open Bio* 8 (2018) 664–670.
- [47] H. Suzuki, K. Kiryluk, J. Novak, Z. Moldoveanu, A.B. Herr, M.B. Renfrow, et al., The pathophysiology of IgA nephropathy, *J. Am. Soc. Nephrol.* 22 (2011) 1795–1803.
- [48] Y. Makita, H. Suzuki, T. Kano, A. Takahata, B.A. Julian, J. Novak, et al., TLR9 activation induces aberrant IgA glycosylation via APRIL- and IL-6-mediated pathways in IgA nephropathy, *Kidney Int.* 97 (2020) 340–349.
- [49] M. Muto, B. Manfro, H. Suzuki, K. Joh, M. Nagai, S. Wakai, et al., Toll-like receptor 9 stimulation induces aberrant expression of a proliferation-inducing ligand by tonsillar germinal center B cells in IgA nephropathy, *J. Am. Soc. Nephrol.* 28 (2017) 1227–1238.