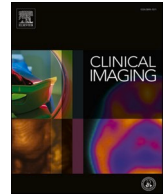




Since January 2020 Elsevier has created a COVID-19 resource centre with free information in English and Mandarin on the novel coronavirus COVID-19. The COVID-19 resource centre is hosted on Elsevier Connect, the company's public news and information website.

Elsevier hereby grants permission to make all its COVID-19-related research that is available on the COVID-19 resource centre - including this research content - immediately available in PubMed Central and other publicly funded repositories, such as the WHO COVID database with rights for unrestricted research re-use and analyses in any form or by any means with acknowledgement of the original source. These permissions are granted for free by Elsevier for as long as the COVID-19 resource centre remains active.



Breast Imaging

Supraclavicular lymphadenopathy after COVID-19 vaccination in Korea: serial follow-up using ultrasonography

Bomi Kim^a, Yoonseon Park^b, Eun Kyung Kim^c, Seung Hyun Lee^{a,*}^a Department of Radiology, National Health Insurance Service Ilsan Hospital, 100 Ilsan-ro, Ilsandong-gu, Goyang-si, Gyeonggi-do 10444, Republic of Korea^b Department of Internal Medicine, National Health Insurance Service Ilsan Hospital, 100 Ilsan-ro, Ilsandong-gu, Goyang-si, Gyeonggi-do 10444, Republic of Korea^c Department of Pathology, National Health Insurance Service Ilsan Hospital, 100 Ilsan-ro, Ilsandong-gu, Goyang-si, Gyeonggi-do 10444, Republic of Korea

ARTICLE INFO

Keywords:

COVID-19

Vaccines

Lymphadenopathy

Ultrasonography

ABSTRACT

We present serial sonographic findings of a case of supraclavicular lymphadenopathy that occurred after COVID-19 vaccination. Ipsilateral lymphadenopathy near the vaccine injection site following COVID-19 vaccination is a rather uncommon but expected adverse reaction. While axillary lymphadenopathy is more common, cases of supraclavicular lymphadenopathy in the setting of recent vaccination against COVID-19 are also being reported. Radiologists as well as referring physicians should be aware of this self-limiting process along with its ultrasonographic features and manage patients conservatively rather than performing an unnecessary immediate biopsy.

1. Introduction

Vaccination against COVID-19 is currently being performed worldwide. Recognizing possible adverse reactions associated with this vaccination is mandatory for clinicians to distinguish expected transient responses following vaccination from actual pathologic processes. Several recent articles reported lymphadenopathy ipsilateral to the vaccination arm after COVID-19 vaccination, especially mRNA vaccines (i.e. Pfizer–BioNTech and Moderna vaccines).^{1–4} Most of them were axillary lymphadenopathy and less commonly supraclavicular lymphadenopathy. This case report presents a patient with supraclavicular lymphadenopathy after COVID-19 vaccination and associated ultrasonographic features seen in serial follow-up.

2. Case description

A 36-year-old female patient visited our hospital due to palpable lesions in the left supraclavicular area. She had been complaining of discomfort in the left lateral and posterior neck for a week. The patient had swelling local inflammatory symptoms and tenderness, but no systemic symptoms such as fever or malaise. She did not have any prior medical history including cancer. Ultrasonography revealed multiple (>five) lymph nodes, which had a short-axis diameter of 0.7 cm or less, at level V (posterior triangle) of her left neck, especially in the

supraclavicular area. The lymph nodes were round (short-axis/long-axis ratio greater than 0.5) and showed a thickened cortex with loss of normal fatty hilum and an ill-defined border with perinodal fat hyper-echogenicity (Fig. 1A, B). There were no abnormal lymph nodes in the right supraclavicular area or other lymph node levels of the neck. Several (≤five) normal lymph nodes with small size (<0.5 cm in short-axis diameter) and without abnormal morphology were observed in bilateral axillae, more of them on the left side. Possibility of lymphadenitis and even Kikuchi disease was suggested considering that the patient was an Asian female and there was unilateral nodal involvement at level V. Ultrasonography-guided core needle biopsy of the supraclavicular lymph nodes was performed. The lymph nodes were mobile while performing the biopsy. Pathological results showed reactive inflammatory signs with predominant small mature T-lymphoid cells with small mature B-lymphoid cells and a negative Epstein–Barr virus-encoded small RNA result.

Further investigation revealed that the patient had received an intramuscular administration of COVID-19 vaccine (Pfizer–BioNTech) on her left arm 17 days before detecting palpable lymph nodes in the left supraclavicular region, where she had been experiencing discomfort for a week. Therefore, we considered that the supraclavicular lymphadenopathy occurred 10 days after the vaccination as an adverse reaction following immunization. She did not have any other adverse reaction including fever, chills, or myalgia following the vaccination. The patient

* Corresponding author.

E-mail addresses: mdspring@nhmc.or.kr (B. Kim), ys0518@nhmc.or.kr (Y. Park), dalsoon2@nhmc.or.kr (E.K. Kim), circle1128@gmail.com (S.H. Lee).<https://doi.org/10.1016/j.clinimag.2021.05.031>

Received 23 April 2021; Received in revised form 23 May 2021; Accepted 31 May 2021

Available online 5 June 2021

0899-7071/© 2021 Elsevier Inc. All rights reserved.

was advised to take nonsteroidal anti-inflammatory drugs for pain control and to get the second vaccination on the contralateral right arm.

The patient completed the second dose of COVID-19 vaccination on the right arm. The patient detected newly developed palpable lesions in the right supraclavicular area a day after the vaccination. Ultrasonography was performed four days after the second vaccination, which was a one-week follow-up of the first ultrasound. The patient's pain in the left supraclavicular region resolved. Left supraclavicular lymph nodes showed a decreased size and extent of perinodal fat hyperechogenicity (Fig. 1C and D). There were several newly developed small lymph nodes that were oval in shape (short-axis/long-axis ratio less than 0.5) in the right supraclavicular area (Fig. 2A). Another one-week follow-up sonography demonstrated further size decrease in both left and right supraclavicular lymph nodes (Figs. 1E, F, and 2B, respectively) with normalization of cortical thickness and some identifiable fatty hilum.

3. Discussion

We report a case of ipsilateral supraclavicular lymphadenopathy confirmed as reactive lymphadenopathy following administration of the Pfizer–BioNTech vaccine against COVID-19. The enlarged supraclavicular lymph nodes showed a size decrease with normalization of morphology on 1-week and 2-week serial follow-up ultrasound.

Vaccination-associated adenopathy occurs in the ipsilateral axillary and/or supraclavicular regions related to local immune response activation.^{3,5} In the Pfizer–BioNTech COVID-19 vaccine trial, the self-

reported rate of ipsilateral axillary and supraclavicular lymphadenopathy was 0.3% among vaccine recipients.⁶ In the Moderna COVID-19 vaccine trial, lymphadenopathy was reported as an adverse event in 1.1% of patients.⁷ The location of lymphadenopathy after COVID-19 vaccination has been much more common in the axillary region than the supraclavicular region in recently published articles.^{1–4}

There have been only a few reports of supraclavicular lymphadenopathy after COVID-19 vaccination in the United States,^{8,9} the United Kingdom,¹⁰ Israel,¹¹ and Spain.⁵ This current report is the first reported case in Asia. Based on a literature review, we found that supraclavicular lymphadenopathy following COVID-19 vaccination predominantly affects women and generally appears in the first 10–15 days (up to 24 days) after vaccine administration. It typically resolves within a month, even though some lymph nodes do remain enlarged after six weeks.¹

This case report demonstrated ultrasonographic features of supraclavicular lymph nodes that developed after COVID-19 vaccination. The nodes were initially enlarged with a thickened cortex, an ill-defined border with perinodal fat hyperechogenicity, and loss of normal fatty hilum. Sonographic findings in reported supraclavicular lymphadenopathy cases following the COVID-19 vaccine vary, but most show an enlarged size and thickened cortex with or without loss of normal fatty hilum.^{8–11} Sonographic findings of axillary lymphadenopathy after the COVID-19 vaccine have similar features,^{3,8,9,11} but supraclavicular lymph nodes tend to show more round rather than elongated shapes with prominently thickened cortices and less preserved normal fatty hilum. Radiologists should be familiar with these sonographic findings

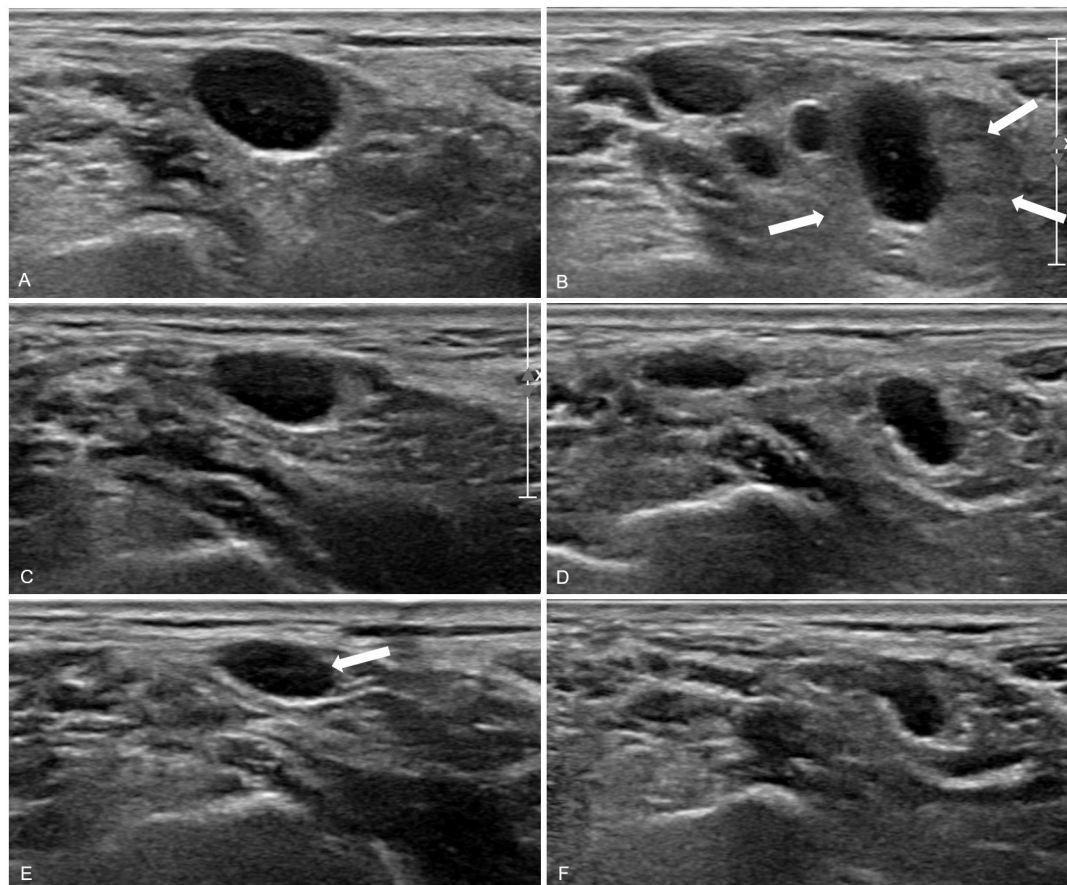


Fig. 1. Left supraclavicular lymphadenopathy that developed 10 days after the first dose of Pfizer–BioNTech COVID-19 vaccine in the left arm. (A and B) Ultrasonography performed on the left supraclavicular region 18 days after the first dose of vaccination demonstrated multiple enlarged (measuring 1.2×0.7 cm and 0.9×0.7 cm, respectively), cortically thickened lymph nodes with loss of normal fatty hilum and an ill-defined border with perinodal fat hyperechogenicity (marked arrows in B). (C and D) One-week follow-up sonography showed decreased size (measuring 0.8×0.4 cm and 0.7×0.5 cm, respectively) and decreased extent of perinodal fat hyperechogenicity of the lymph nodes. (E and F) Another one-week follow-up sonography showed further decreased size (measuring 0.8×0.3 cm and 0.5×0.3 cm, respectively) of the nodes with normalization of cortical thickness and some identifiable fatty hilum (marked arrow in E).

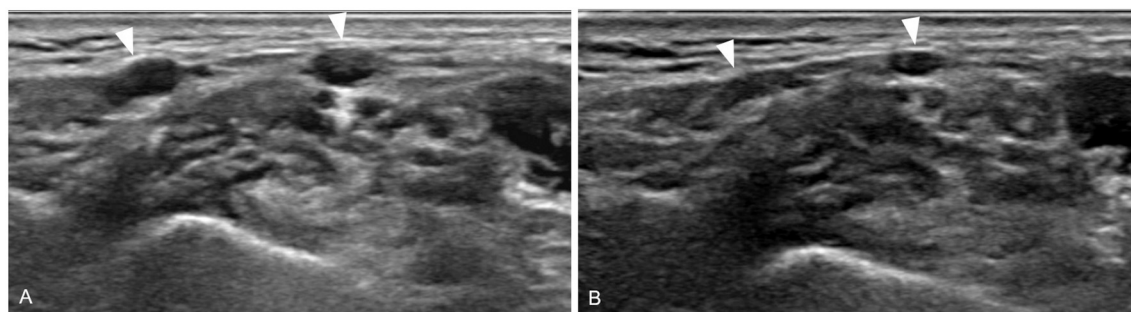


Fig. 2. Right supraclavicular lymph nodes that developed one day after the second dose of Pfizer–BioNTech COVID-19 vaccine in the right arm. (A) Ultrasonography performed on the right supraclavicular region four days after the second dose of vaccination demonstrated several small (the largest measuring 0.5×0.2 cm) lymph nodes (marked arrowheads) without cortical thickening and with preserved fatty hilum. (B) One-week follow-up sonography showed decreased size of the nodes.

to not misinterpret these lymph nodes as pathologic conditions as long as the patient has a recent history of COVID-19 vaccination.

Lymphadenopathy after COVID-19 vaccination can confuse physicians, as the differential diagnosis for unilateral axillary or supraclavicular lymphadenopathy is broad, and includes inflammation, infection, and malignancy such as a metastatic lymph node or lymphoma. Imaging should be performed prior to vaccination or postponed for at least 4–6 weeks after COVID-19 vaccination unless a patient has an urgent clinical indication.¹ When imaging is required after vaccination, institutions should document COVID-19 vaccination information, including date(s) of vaccination(s), injection site(s) [left or right, arm or thigh], and type of vaccine in a patient questionnaire that is readily available to radiologists.^{1,4} Recognition of supraclavicular lymphadenopathy as a self-limiting immune reaction in the setting of recent ipsilateral arm vaccination against COVID-19 may reassure patients and avoid unnecessary aspiration or biopsy of lymph nodes. More conservative approaches, such as observation for at least 6 weeks until resolution or short-term follow-up with ultrasound to ensure resolution of lymph nodes, are recommended rather than immediate biopsy of the nodes in patients with axillary and/or supraclavicular lymphadenopathy after recent ipsilateral COVID-19 vaccination.^{1,9}

Declaration of competing interest

None of the authors have any conflict of interest to disclose.

Acknowledgements

None.

References

- [1] Becker AS, Perez-Johnston R, Chikarmane SA, et al. Multidisciplinary recommendations regarding post-vaccine adenopathy and radiologic imaging: radiology scientific expert panel. *Radiology* Feb 24 2021;210436. <https://doi.org/10.1148/radiol.2021210436>.
- [2] Edmonds CE, Zuckerman SP, Conant EF. Management of unilateral axillary lymphadenopathy detected on breast MRI in the era of coronavirus disease (COVID-19) vaccination. *AJR Am J Roentgenol* 2021. <https://doi.org/10.2214/AJR.21.25604>.
- [3] Mehta N, Sales RM, Babagbemi K, et al. Unilateral axillary adenopathy in the setting of COVID-19 vaccine. *Clin Imaging* 2021;75:12–5.
- [4] Lehman CD, D'Alessandro HA, Mendoza DP, Succi MD, Kambadakone A, Lamb LR. Unilateral lymphadenopathy after COVID-19 vaccination: a practical management plan for radiologists across specialties. *J Am Coll Radiol* June 01, 2021;18(6): P843–52.
- [5] Fernandez-Prada M, Rivero-Calle I, Calvache-Gonzalez A, Martinon-Torres F. Acute onset supraclavicular lymphadenopathy coinciding with intramuscular mRNA vaccination against COVID-19 may be related to vaccine injection technique, Spain, January and February 2021. *Euro Surveill* 2021;26(10).
- [6] Polack FP, Thomas SJ, Kitchin N, et al. Safety and efficacy of the BNT162b2 mRNA Covid-19 vaccine. *N Engl J Med* 2020;383(27):2603–15.
- [7] Local reactions, systemic reactions, adverse events, and serious adverse events: Moderna COVID-19 vaccine. <https://www.cdc.gov/vaccines/covid-19/info-by-product/moderna/reactogenicity.html>. [Accessed 21 May 2021].
- [8] Ozutemiz C, Krystosek LA, Church AL, Chauhan A, Ellermann JM, Domingo-Musibay E, et al. Lymphadenopathy in COVID-19 vaccine recipients: diagnostic dilemma in oncology patients. *Radiology* 2021;210275.
- [9] Washington T, Bryan R, Clemow C. Adenopathy following COVID-19 vaccination. *Radiology* 2021;299:E280–1. 210236.
- [10] Mitchell OR, Dave R, Bekker J, Brennan PA. Supraclavicular lymphadenopathy following COVID-19 vaccination: an increasing presentation to the two-week wait neck lump clinic? *Br J Oral Maxillofac Surg* 2021;59(3):384–5.
- [11] Hiller N, Goldberg SN, Cohen-Cymberknoh M, Vainstein V, Simanovsky N. Lymphadenopathy associated with the COVID-19 vaccine. *Cureus* 2021;13(2): e13524.