


## Images in Rheumatology

# Livedo Reticularis After COVID-19 Vaccination

Taro Horino , MD, PhD, Department of Endocrinology, Metabolism, and Nephrology, Kochi Medical School, Kochi University; Satoshi Inotani, MD, PhD, Department of Endocrinology, Metabolism, and Nephrology, Kochi Medical School, Kochi University; Kimiko Nakajima, MD, PhD, Department of Dermatology, Kochi Medical School, Kochi University; Yoshio Terada, MD, PhD, Department of Endocrinology, Metabolism, and Nephrology, Kochi Medical School, Kochi University, Kochi, Japan. Address correspondence to Dr. T. Horino, Department of Endocrinology, Metabolism and Nephrology, Kochi Medical School, Kochi University, Kohasu, Oko-cho, Nankoku, Kochi 783-8505, Japan. Email: horinott@yahoo.co.jp. The authors declare no conflicts of interest relevant to this article. Ethics board approval was not required because this is a single case report, and no intervention was provided to the patient during this research. Written informed consent was obtained from the patient to publish the material.

Livedo reticularis occurs when there is increased visibility of the venous plexus, often caused by reduced arterial inflow or venodilation.<sup>1</sup> Although livedo reticularis has been reported in patients with COVID-19,<sup>2,3</sup> it has also been reported following COVID-19 vaccination.<sup>4</sup>

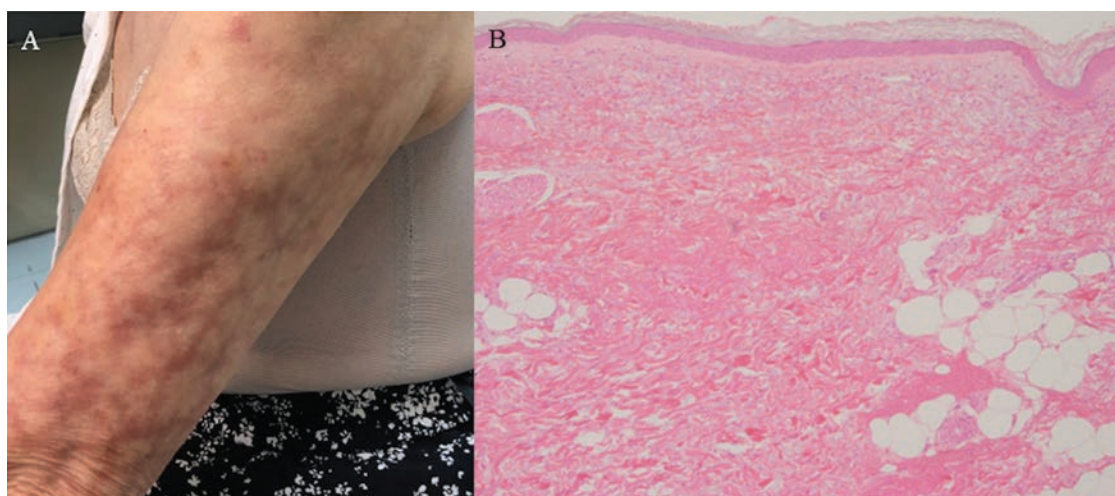
An 80-year-old woman presented with eruption. She had received a third dose of the coronavirus disease 2019 (COVID-19) vaccine (Pfizer-BioNTech9) 40 days prior to presentation and had high fever and pain at the injection site for a week. The day following vaccination, livedo reticularis was observed at the injection site on her left upper arm and its periphery, with intense redness that gradually faded and pigmented but did not disappear (Figure 1A). Laboratory examination revealed elevated C-reactive protein (0.58 mg/dL; normal range < 0.15) but no remarkable findings of coagulation, autoimmune diseases, or infectious diseases. Skin tissue biopsy showed mild infiltration and edematous changes of inflammatory cells around the small blood vessels from the superficial dermis to the boundary with subcutaneous fat, which were consistent with livedo reticularis (Figure 1B). No recurrence of fever and pain was observed after presentation, and there was no exacerbation of the eruption. Since her symptoms did not worsen after that, the

patient was followed up for half a year without treatment. The rash gradually faded; however, the pigmentation did not disappear.

In postvaccination cases, endotheliosis and vasoconstriction have been hypothesized as mechanisms that lead to livedo reticularis during COVID-19 infection<sup>3</sup> or after COVID-19 vaccination.<sup>4</sup> Our findings suggest that COVID-19 vaccination may induce livedo reticularis local to the inoculation site in patients receiving anticoagulant therapy.

## REFERENCES

1. Freeman EE, McMahon DE, Lipoff JB, et al. The spectrum of COVID-19-associated dermatologic manifestations: an international registry of 716 patients from 31 countries. *J Am Acad Dermatol* 2020;83:1118-29.
2. Khalil S, Hinds BR, Manalo IF, Vargas IM, Mallela S, Jacobs R. Livedo reticularis as a presenting sign of severe acute respiratory syndrome coronavirus 2 infection. *JAAD Case Rep* 2020;6:871-4.
3. McMahon DE, Amerson E, Rosenbach M, et al. Cutaneous reactions reported after Moderna and Pfizer COVID-19 vaccination: a registry-based study of 414 cases. *J Am Acad Dermatol* 2021;85:46-55.
4. Mintz MA, Jariwala N, Fang V, Coromilas A, Rosenbach M. Livedo reticularis on bilateral knees after the third dose of messenger RNA-1273 SARS-CoV-2 vaccine. *JAAD Int* 2022;7:52-3.



**Figure 1.** Macroscopic and histological findings of livedo reticularis in the present case. (A) Livedo reticularis is observed at the injection site in the left upper arm and its periphery 40 days after the third dose of COVID-19 vaccination. (B) Skin biopsy specimen showing mild infiltration and edematous changes of inflammatory cells such as lymphocytes and plasma cells around the small blood vessels from the superficial dermis to the boundary with subcutaneous fat, 41 days after the third dose of COVID-19 vaccination (H&E staining, original magnification 200 $\times$ ). COVID-19: coronavirus disease 2019.