




Since January 2020 Elsevier has created a COVID-19 resource centre with free information in English and Mandarin on the novel coronavirus COVID-19. The COVID-19 resource centre is hosted on Elsevier Connect, the company's public news and information website.

Elsevier hereby grants permission to make all its COVID-19-related research that is available on the COVID-19 resource centre - including this research content - immediately available in PubMed Central and other publicly funded repositories, such as the WHO COVID database with rights for unrestricted research re-use and analyses in any form or by any means with acknowledgement of the original source. These permissions are granted for free by Elsevier for as long as the COVID-19 resource centre remains active.



Letter to the Editor

Erythema nodosum triggered by BNT162b2 mRNA COVID-19 vaccine


Dear Editor,

Erythema nodosum (EN) is a common skin manifestation of various inflammatory, infectious and malignant diseases. Its pathogenesis is poorly understood, possibly related to a type-IV delayed hypersensitivity reaction resulting from exposure to various antigens. Recently, EN was reported in rare cases of severe acute respiratory syndrome coronavirus-2 (SARS-CoV-2)-infected patients [1]. Here, we report a case of EN occurring after the first mRNA coronavirus disease-2019 (COVID-19) vaccine shot.

A 39-year-old female (158 cm/55 kg) presented with several non-symmetrical painful violaceous nodules of 1–3 cm diameter of the left forearm and both shins. Six months ago, she was admitted to hospital with moderate-to-severe hypoxemic COVID-19-related pneumonia treated with 10-day course of 6 mg/day dexamethasone. She reported that the lesions developed 48 h after the first injection of Pfizer-BioNTech BNT162b2 mRNA COVID-19 vaccine 20 days ago. She did not report a recent infectious episode or drug exposure. She did not complain about fever, headache, arthralgia or weakness. Physical examination revealed typical EN (Fig. 1) without palpable lymphadenopathy or other abnormalities. Standard RT-PCR technique performed using swab in her upper respiratory airways (Cobas® SARS-CoV-2 kit; sensitivity limit, 40-cycles) was negative. Routine blood tests were unremarkable including negative pregnancy test and normal inflammatory markers. Antistreptolysin antibodies were undetectable. Serum angiotensin converting enzyme was in the normal range. Stool culture and hepatitis B, hepatitis C and HIV serology were negative. Tuberculin skin test was negative. Chest X-ray was normal excluding sarcoidosis and tuberculosis. The patient was treated with 180 mg/day fexofenadine, 40 mg/day prednisone and topical corticosteroids during 5 days. The lesions regressed according to the biligenesis shades and totally disappeared one month later. The intrinsic score (I) using the 2011 French method for adverse drug reactions [2] was I6, combining the chronological (C) and semiological (S) scores of C3 and S3, respectively.

EN is the most frequent presentation of panniculitis, typically occurring in the 20–40 year-old female, as bilateral erythematous painful nodules sitting on the extensor side of lower limbs and self-resolving within two months like in our case. Diagnosis is clinical. In our young patient without medical history, no alternative etiology was found except COVID-19 vaccine administered in one-shot as recommended 6 months post-COVID-19. Because of typical dermatological presentation, no skin biopsy was done.

EN is uncommon in COVID-19 patients [1]. Although SARS-CoV-2 can infect skin cells that express angiotensin-converting enzyme-2, EN genesis was attributed to the excessive inflammatory response with the so-called cytokine storm triggered by the viral infection, possibly in the presence of individual susceptibility related to gene polymorphisms (e.g. of interleukin-1beta gene and interleukin-6 gene promotor), like previously reported in EN patients [3,4].

EN was also previously attributed to various vaccines including Bacille-Calmette-Guerin, human papillomavirus, hepatitis B, typhoid, cholera, rabies, smallpox, tetanus, diphtheria and pertussis [5]. Recently, EN was reported 48 h after the second injection of the non-mRNA Oxford/AstraZeneca ChAdOx1 nCoV-19 (AZD1222) vaccine in a 66-year-old female with a breast cancer in remission [6]. In vaccine-triggered cases, EN was hypothesized to result from immune response to the mild infection mimicked by the vaccine. Our case supports that EN may also result from mRNA vaccine, which shares common immune pathways with COVID-19. Noteworthy, like in the other case of post- COVID-19 vaccine, EN occurred in our patient after the second exposure to the Spike protein.

To conclude, physicians should be aware that EN might be triggered by mRNA Covid-19 vaccine, even in the absence of underlying disease. However, in our case, we cannot rule out a possible role of the previous SARS-CoV-2 infection in this unusual vaccine-attributed skin manifestation.

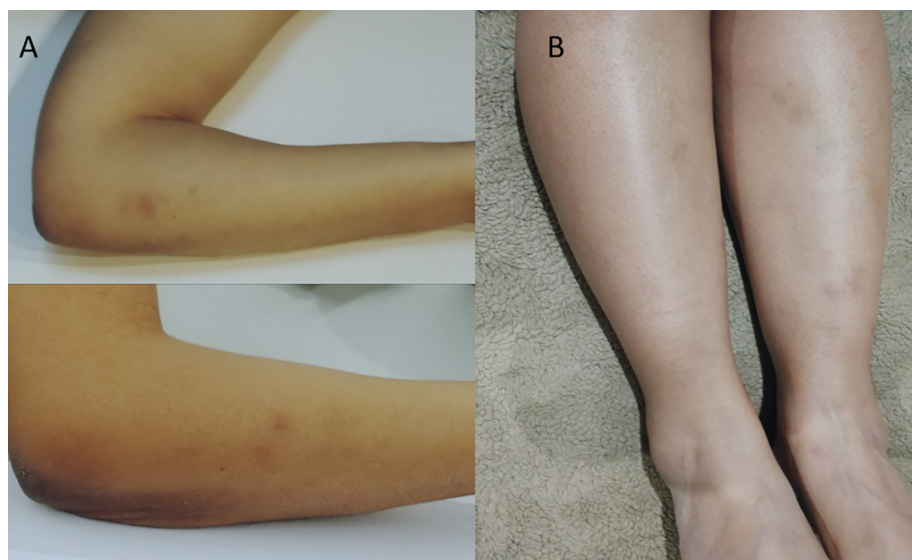


Fig. 1. mRNA COVID-attributed erythema nodosum on the left forearm (A) and legs (B).

Funding

None.

Declaration of Competing Interest

The authors declare that they have no known competing financial interests or personal relationships that could have appeared to influence the work reported in this paper.

References

- [1] Conforti C, Dianzani C, Agozzino M, Giuffrida R, Marangi GF, di Meo N, et al. Cutaneous Manifestations in Confirmed COVID-19 Patients: a Systematic Review. *Biology* (Basel) 2020;9(12):449. <https://doi.org/10.3390/biology9120449>.
- [2] Miremont-Salamé G, Théophile H, Haramburu F, Bégaud B. Causality assessment in pharmacovigilance: the French method and its successive updates. *Thérapie* 2016;71(2):179–86.
- [3] Amoli MM, Miranda-Filloy JA, Vazquez-Rodriguez TR, Ollier WE, Gonzalez-Gay MA. Interleukin-1 beta gene polymorphism in patients with biopsy-proven erythema nodosum. *Clin Exp Rheumatol* 2011;29(1 Suppl 64):S131–2.
- [4] Amoli MM, Miranda-Filloy JA, Fernandez-Diaz ML, Martin J, Ollier WE, Gonzalez-Gay MA. Interleukin-6 promoter polymorphism at position -174 in biopsy-proven patients with erythema nodosum from a defined population. *Clin Exp Rheumatol* 2008;26(3 Suppl 49):S155–6.
- [5] Cohen PR. Combined reduced-antigen content tetanus, diphtheria, and acellular pertussis (tdap) vaccine-related erythema nodosum: case report and review of

vaccine-associated erythema nodosum. *Dermatol Ther* (Heidelb) 2013;3(2):191–7.

- [6] Hali F, Marmech C, Chiheb S and Alatawna H. Erythema Nodosum Manifestation Post COVID-19 Vaccine: A Case Report. *World Journal of Vaccines* 2021, 33–38. <https://www.scirp.org/journal/paperinformation.aspx?paperid=110965>. Accessed on August 29, 2021.

Vanessa Juddoo

Department of Endocrinology and Diabetology, Lariboisière Hospital, Paris, France

Sonia Juddoo

Department of Geriatrics, Avicenne Hospital, Bobigny, France

Bruno Mégarbane*

Department of Medical and Toxicological Critical Care, Lariboisière Hospital, Paris University, INSERM UMRS-1144 Paris, France

* Address: Réanimation Médicale et Toxicologique, Hôpital Lariboisière, 2 Rue Ambroise Paré, 75010 Paris, France.

E-mail address: bruno.megarbane@lrb.aphp.fr

Received 29 August 2021

Accepted 21 March 2022

Available online 28 March 2022