




Since January 2020 Elsevier has created a COVID-19 resource centre with free information in English and Mandarin on the novel coronavirus COVID-19. The COVID-19 resource centre is hosted on Elsevier Connect, the company's public news and information website.

Elsevier hereby grants permission to make all its COVID-19-related research that is available on the COVID-19 resource centre - including this research content - immediately available in PubMed Central and other publicly funded repositories, such as the WHO COVID database with rights for unrestricted research re-use and analyses in any form or by any means with acknowledgement of the original source. These permissions are granted for free by Elsevier for as long as the COVID-19 resource centre remains active.

Available online at [www.sciencedirect.com](http://www.sciencedirect.com)

ScienceDirect

journal homepage: [www.jfma-online.com](http://www.jfma-online.com)

## Case Report

# Pityriasis Rosea-like eruptions following COVID-19 mRNA-1273 vaccination: A case report and literature review

Chii-Shyan Wang <sup>a</sup>, Hsuan-Hsiang Chen <sup>b,\*</sup>, Shih-Hao Liu <sup>c</sup><sup>a</sup> Department of Dermatology, En Chu Kong Hospital, New Taipei City, Taiwan<sup>b</sup> Department of Dermatology, National Taiwan University Hospital and National Taiwan University College of Medicine, Taipei, Taiwan<sup>c</sup> Department of Pathology, En Chu Kong Hospital, New Taipei City, Taiwan

Received 15 September 2021; received in revised form 20 October 2021; accepted 28 December 2021

## KEYWORDS

COVID-19;  
mRNA vaccine;  
Pityriasis rosea

Pityriasis rosea (PR) is a self-limited disease with exanthematous papulosquamous rashes mostly associated with reactivation of human herpesvirus (HHV)-6 or HHV-7. PR-like eruptions, which occur along with peripheral eosinophilia, interface dermatitis, and eosinophils on histopathology, may result from medications or vaccinations. Previously, PR-like eruptions had been noted following vaccination for influenza or other vaccines. During this pandemic, acute COVID-19 infection has been related to PR or PR-like eruptions in several cases. Various COVID-19 vaccines associated with PR-like eruptions were rarely reported. Herein, we report a case of cutaneous PR-like eruptions following COVID-19 mRNA-1273 vaccination.

Copyright © 2022, Formosan Medical Association. Published by Elsevier Taiwan LLC. This is an open access article under the CC BY-NC-ND license (<http://creativecommons.org/licenses/by-nc-nd/4.0/>).

## Introduction

Pityriasis rosea (PR) is a self-limited exanthematous papulosquamous disease, usually associated with reactivation of either human herpesvirus (HHV)-6 or HHV-7, while PR-like eruptions are reactions to vaccinations or medications.<sup>1</sup> PR or PR-like rashes have been identified after vaccination against H1N1 influenza, human papillomavirus, smallpox,

poliomyelitis, hepatitis B, diphtheria, pneumococcal infections, and tuberculosis.<sup>1–3</sup> During this pandemic, COVID-19 has been associated with PR or PR-like eruptions following acute infection.<sup>4,5</sup> PR-like eruptions were also reported to be associated with different COVID-19 vaccines.<sup>6,7</sup> The exact pathogenetic mechanism that leads to PR or PR-like eruptions after infection or vaccination is still unclear. Herein, we report a case of cutaneous PR-like eruptions following COVID-19 mRNA-1273 (Moderna) vaccination.

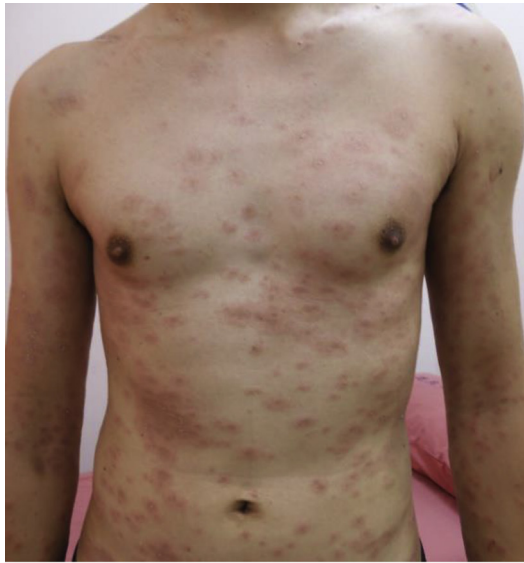## Case report

A 40-year-old male patient developed skin rash seven days after the first dose of the COVID-19 mRNA-1273 vaccine.

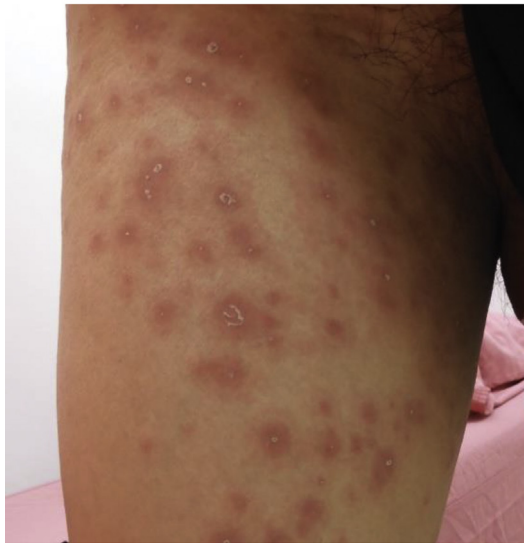\* Corresponding author. Department of Dermatology, National Taiwan University Hospital, 7, Chung-Shan South Road, Taipei, Taiwan. Fax: +886 2 2393 4177.

E-mail address: [beauty101@gmail.com](mailto:beauty101@gmail.com) (H.-H. Chen).

The severe itching skin lesions developed over the lower abdomen initially, but spread to the neck, trunk, and four limbs afterward. There were no fever, myalgia, or other associated systemic symptoms. The patient had urticaria several months ago, but denied any history of recent infections, drug exposure, contact with COVID-19 patients, or similar skin rashes in personal or family history. Urticaria was diagnosed at another clinic and treated with oral antihistamines. His urticaria showed no obvious improvement, so a hypersensitivity reaction to COVID-19 mRNA-1273 vaccination was suspected. The patient was given systemic prednisolone 15 mg/day, but the skin lesions persisted.



(a)

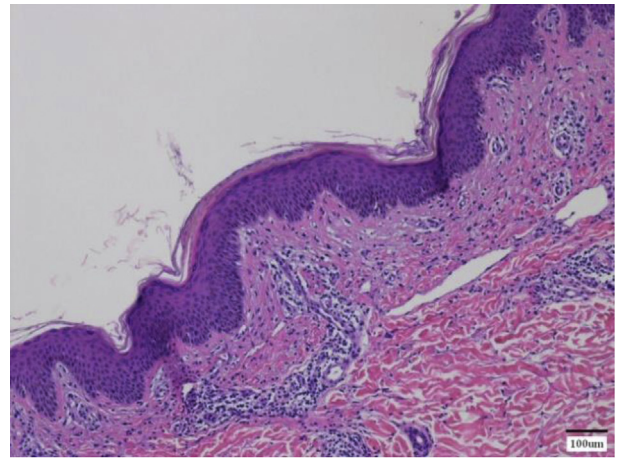


(b)

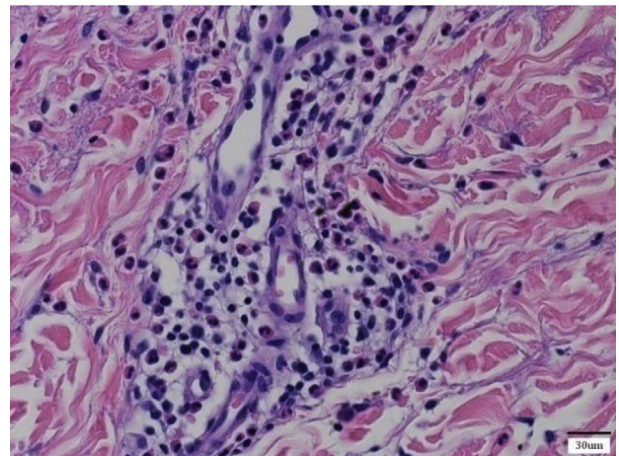
**Figure 1** (a) Multiple oval erythematous plaques with peripheral scales over the trunk and proximal extremities. (b) Close-up of plaques with the trailing scales.

Ten days after the onset of the rash, he came to our dermatology outpatient clinic for further evaluation of the skin rashes. The cutaneous examination revealed multiple variously sized oval erythematous papules and plaques with central darkening and collarette scales over the neck, trunk, back, and four limbs (Fig. 1). No herald patch, oral or genital lesions were noted. He had no oropharyngeal lesions, either. These plaques on the patient's body were slightly distributed along the cleavage lines with a Christmas tree pattern.

Histopathological examination demonstrated scattered foci of angulated parakeratosis with slight acanthosis and mild spongiosis in the epidermis as well as mixed lymphohistiocytic and eosinophilic infiltrates surrounding the perivascular spaces in the superficial dermis (Fig. 2). No basal hydropic degeneration was noted. These findings were compatible with PR or PR-like drug hypersensitivity reaction. However, the patient did not accept other



(a)



(b)

**Figure 2** (a) Histopathological findings of scattered foci of angulated parakeratosis with slight acanthosis and mild spongiosis in the epidermis (Skin, original magnification x100, H&E). (b) Mixed lymphohistiocytic and eosinophilic infiltrates surrounds the perivascular spaces in the superficial dermis (Skin, original magnification x400, H&E).

investigatory laboratory examinations. The patient was treated with oral prednisolone 30 mg/day for five days and tapered gradually in the following two weeks. There was no recurrence of the skin lesions after a follow-up for two months.

## Discussion

PR or PR-like rashes have been described after vaccination against H1N1 influenza, human papillomavirus, diphtheria, poliomyelitis, smallpox, pneumococcal infections, hepatitis B, and tuberculosis.<sup>1</sup> According to the criteria proposed by Drago et al., typical PR rather than PR-like eruptions were considered if there were non-itching discrete exanthematous lesions with the herald patch, no eosinophilia in the peripheral blood count, and no eosinophils in the histopathological findings.<sup>8</sup> Our patient likely had PR-like eruptions due to the lack of herald patch, severe itching, and eosinophils in the histopathological findings. Because he did not accept other investigatory laboratory examinations, the eosinophil count in the blood as well as the antibody titers of HHV-6 and HHV-7 were unavailable.

PR or PR-like eruptions after the COVID-19 vaccination are rarely reported (Table 1). According to a 405 cases series reported by Català et al., cutaneous reactions after COVID-19 vaccination were classified as injection-site (COVID-ARM, 32.1%), urticaria (14.6%), morbilliform (8.9%), papulovesicular (6.4%), PR-like (4.9%) and purpuric (4%) reactions.<sup>6</sup> The incidences of BNT162b2, mRNA-1273, and AZD1222 related PR-like cutaneous reactions were

6.7%, 3.4%, and 4.2%, respectively. In another registry-based study of 414 cases by McMahon et al., only four cases (0.97%) of PR-like eruptions after COVID-19 vaccination were described.<sup>7</sup> The incidences of the first dose BNT162b2 and mRNA-1273 vaccine-related PR were 5.9% and 0.4%, respectively. Recently, a case series of 31 patients with PR following COVID-19 vaccination revealed that 45.2% (14 cases) had received BNT162b2 mRNA vaccine, while 54.8% (17 cases) had received inactivated CoronaVac vaccine.<sup>9</sup> The average onset time was 12.7 days following vaccination, and patients recovered in 7.8 weeks on average after treatment with topical corticosteroids and oral antihistamines. Remarkably, a higher percentage of PR after inactivated COVID-19 vaccine injection was noted.

Adya et al. reported a patient whose cutaneous histopathologic examination revealed epidermal spongiosis, perivascular lymphocytic infiltrate in the papillary dermis, and extravasated red blood cells in the papillary and reticular dermis.<sup>10</sup> Another study by Akdas et al. demonstrated focal parakeratosis in mounds with exocytosis of lymphocytes, spongiosis in the epidermis, and extravasated red blood cells in the dermis.<sup>11</sup> Cyrenne et al. described the lesional biopsy result with parakeratosis, interface changes, and scattered dyskeratotic keratinocytes.<sup>12</sup> The pathological findings in our patient showed parakeratosis with slight acanthosis and mild spongiosis in the epidermis. Mixed lymphohistiocytic and eosinophilic infiltrates surrounding the perivascular spaces in the superficial dermis were also noted. Although these findings were compatible with PR-like eruptions, the eosinophilic

**Table 1** PR or PR-like eruptions after COVID-19 vaccination.

Study	No	Age	Sex	Vaccine	Treatment	Underlying Dz
Català et al. <sup>6</sup>	11	N.A. <sup>a</sup>	N.A.	BNT162b2	N.A.	N.A.
	5	N.A.	N.A.	mRNA-1273	N.A.	N.A.
	4	N.A.	N.A.	AZD1222	N.A.	N.A.
McMahon et al. <sup>7</sup>	3	N.A.	N.A.	BNT162b2	N.A.	N.A.
	1	N.A.	N.A.	mRNA-1273	N.A.	N.A.
Temiz et al. <sup>9</sup>	14	27–61	4M10F	BNT162b2	O.A. <sup>b</sup> + T.C. <sup>c</sup>	—
	17	26–59	9M8F	Corona Vac	O.A + T.C.	—
Adya et al. <sup>10</sup>	1	21	M	ChAdOx1 nCoV-19	N.A.	—
Akdaş et al. <sup>11</sup>	1	45	F	Corona Vac	O.A + T.C.	—
Cyrenne et al. <sup>12</sup>	2	20+	F	BNT162b2	T.C.	Alopecia areata
		40+	M	BNT162b2	O.A + doxycycline	—
Marcantonio-Santa Cruz et al. <sup>13</sup>	2	22	F	BNT162b2	—	N.A.
		54	F	BNT162b2	T.C.	N.A.
Busto-Leis et al. <sup>14</sup>	2	26	N.A.	BNT162b2	N.A.	N.A.
		29	M	BNT162b2	N.A.	N.A.
Carballido et al. <sup>15</sup>	1	35	M	BNT162b2	O.A + T.C.	N.A.
Abdullah et al. <sup>16</sup>	1	40	M	mRNA vaccine <sup>d</sup>	T.C.	—
Dormann et al. <sup>17</sup>	1	19	F	AZD1222	—	—
Huang et al. <sup>18</sup>	2	19	M	BIBP-CorV	Valacyclovir + T.C.	N.A.
		51	M	BIBP-CorV	Ganciclovir	—
Current case	1	30	M	mRNA-1273	Oral steroids	Urticaria

<sup>a</sup> N.A.: not available.

<sup>b</sup> O.A.: oral antihistamines.

<sup>c</sup> T.C.: topical corticosteroids.

<sup>d</sup> The type of vaccine was not available.



infiltrates surrounding the perivascular spaces in the superficial dermis were different from those in the previous literature. Only one report by Marcantonio-Santa Cruz et al. showed a superficial perivascular infiltrate with scattered eosinophils in the cutaneous biopsy of the patient.<sup>13</sup> Our patient may have developed a delayed-type hypersensitivity reaction, just like the drug-induced PR-like eruption.

It has been reported previously that PR is a manifestation of COVID-19 infection.<sup>4,19</sup> The exact pathogenetic mechanism that leads to PR or PR-like eruptions after viral infection is still unclear. The SARS-CoV-2 virus spike protein was found on endothelial cells and lymphocytes of PR-like skin lesions, indicating a direct association between SARS-CoV-2 infection and PR.<sup>5</sup> It is also possible that SARS-CoV-2 infection may distract the cell-mediated control of HHV-6 or HHV-7, resulting in the reactivation of herpes viruses and PR manifestation.<sup>20,21</sup>

Several mechanisms may explain the PR or PR-like eruptions development after COVID-19 vaccination. Firstly, it was suspected that cell-mediated immune response may develop against the molecular structural mimicry of the specific viral epitope after vaccination.<sup>2,3</sup> Secondly, the COVID-19 vaccine may trigger PR by reactivation of HHV-6 or HHV-7. Català et al. hypothesized that a strong specific immune response against SARS-CoV-2 or the S protein from vaccines may distract the cell-mediated control of another latent virus.<sup>6</sup> Whether driven by vaccines, infections, drugs, or other factors, immune-related herpes virus reactivation may be involved in the pathogenesis of PR or PR-like eruptions. However, the serological evidence for HHV-6/7 reactivation following COVID-19 vaccination is not found in the literature. Thirdly, vaccines may trigger a delayed-type systemic hypersensitivity response, similar to medication-induced PR-like eruptions.

In conclusion, we report a case of cutaneous PR-like eruptions with eosinophils in the histopathological findings following COVID-19 mRNA-1273 vaccine injection. Further studies on direct tissue and serological examination for evidence of HHV-6 and HHV-7 reactivation are mandatory to confirm the causative link between PR-like eruptions and COVID-19 vaccination.

## Patient consent

The patient in this manuscript has given oral informed consent to the publication of his case details.

## Declaration of competing interest

None.

## Acknowledgments

The patient in this manuscript has given oral informed consent to the publication of his case details. We would also like to thank Yan-Chen Yeh for editing and reviewing this manuscript for English language.

## References

1. Drago F, Ciccarese G, Javor S, Parodi A. Vaccine-induced pityriasis rosea and pityriasis rosea-like eruptions: a review of the literature. *J Eur Acad Dermatol Venereol* 2016;**30**:544–5.
2. Chen JF, Chiang CP, Chen YF, Wang WM. Pityriasis rosea following influenza (H1N1) vaccination. *J Chin Med Assoc* 2011;**74**:280–2.
3. Papakostas D, Stavropoulos PG, Papafragkaki D, Grigoraki E, Avgerinou G, Antoniou C. An atypical case of pityriasis rosea gigantea after influenza vaccination. *Case Rep Dermatol* 2014;**6**:119–23.
4. Johansen M, Chisolm SS, Aspey LD, Brahmabhatt M. Pityriasis rosea in otherwise asymptomatic confirmed COVID-19—positive patients: a report of 2 cases. *JAAD Case Rep* 2021;**7**:93–4.
5. Welsh E, Cardenas-de la Garza JA, Cuellar-Barboza A, Franco-Marquez R, Arvizu-Rivera RI. SARS-CoV-2 spike protein positivity in pityriasis rosea-like and urticaria-like rashes of COVID-19. *Br J Dermatol* 2021;**184**(6):1194–5.
6. Català A, Muñoz-Santos C, Galván-Casas C, Roncero Riesco M, Revilla Nebreda D, Solà-Truyols A, et al. Cutaneous reactions after SARS-CoV-2 vaccination: a cross-sectional Spanish nationwide study of 405 cases. *BJD* 2021. <https://doi.org/10.1111/bjd.20639>.
7. McMahon DE, Amerson E, Rosenbach M, Lipoff JB, Moustafa D, Tyagi A, et al. Cutaneous reactions reported after Moderna and Pfizer COVID-19 vaccination: a registry-based study of 414 cases. *J Am Acad Dermatol* 2021;**85**:46–55.
8. Drago F, Ciccarese G, Parodi A. Pityriasis rosea and pityriasis rosea-like eruptions: how to distinguish them? *JAAD Case Rep* 2018;**4**:800–1.
9. Temiz SA, Abdelmaksoud A, Dursun R, Durmaz K, Sadoughifar R, Hasan A. Pityriasis rosea following SARS-CoV-2 vaccination: a case series. *J Cosmet Dermatol* 2021;**20**. <https://doi.org/10.1111/jocd.14372>.
10. Adya KA, Inamadar AC, Albadri W. Post Covid-19 vaccination papulovesicular pityriasis rosea-like eruption in a young male. *Dermatol Ther* 2021;**34**:e15040. <https://doi.org/10.1111/dth.15040>.
11. Akdaş E, İlter N, Ögüt B, Erdem Ö. Pityriasis rosea following CoronaVac COVID-19 vaccination: a case report. *J Eur Acad Dermatol Venereol* 2021;**35**(8):e491–3.
12. Cyrenne BM, Al-Mohammed F, DeKoven JG, Alhusayen R. Pityriasis rosea-like eruptions following vaccination with BNT162b2 mRNA COVID-19 Vaccine. *J Eur Acad Dermatol Venereol* 2021;**35**(9):e546–8.
13. Marcantonio-Santa Cruz OY, Vidal-Navarro A, Pesqué D, Giménez-Arnau AM, Pujol RM, Martín-Ezquerro G. Pityriasis rosea developing after COVID-19 vaccination. *J Eur Acad Dermatol Venereol* 2021;**35**. <https://doi.org/10.1111/jdv.17498>.
14. Busto-Leis JM, Servera-Negre G, Mayor-Ibarguren A, Sendagorta-Cudós E, Feito-Rodríguez M, Nuño-González A, et al. Pityriasis rosea, COVID-19 and vaccination: new keys to understand an old acquaintance. *J Eur Acad Dermatol Venereol* 2021;**35**. <https://doi.org/10.1111/jdv.17301>.
15. Carballido Vázquez AM, Morgado B. Pityriasis rosea-like eruption after Pfizer-BioNTech COVID-19 vaccination. *Br J Dermatol* 2021;**185**(2):e34. <https://doi.org/10.1111/bjd.20143>.
16. Abdullah L, Hasbani D, Kurban M, Abbas O. Pityriasis rosea after mRNA COVID-19 vaccination. *Int J Dermatol* 2021;**60**(9):1150–1.
17. Dormann H, Grummt S, Karg M. Pityriasis rosea as a possible complication of vaccination against COVID-19. *Dtsch Arztebl Int* 2021;**118**(25):431.
18. Huang L, Yao Z, Zhang J. Two cases of pityriasis rosea after the injection of coronavirus disease 2019 vaccine. *J Eur Acad*

- Dermatol Venereol* 2021;**36**. <https://doi.org/10.1111/jdv.17648>.
19. Ehsani AH, Nasimi M, Bigdelo Z. Pityriasis rosea as a cutaneous manifestation of COVID-19 infection. *J Eur Acad Dermatol Venereol* 2020;**34**:e436–7.
  20. Drago F, Ciccarese G, Rebora A, Parodi A. Human herpesvirus-6, -7, and Epstein-Barr virus reactivation in pityriasis rosea during COVID-19. *J Med Virol* 2021;**93**:1850–1.
  21. Ciccarese G, Parodi A, Drago F. SARS-CoV-2 as possible inducer of viral reactivations. *Dermatol Ther* 2020;**33**:e13878.