

Necrosis of uveal melanoma post-COVID-19 vaccination

Ajeet M. Wagle^{1,2}, Bing Cheng Wu³, Lingam Gopal⁴,
Gangadhara Sundar⁴

A 49-year-old Indian male presented with rapidly progressive vision loss 1 day after receiving the second dose of BNT162b2 mRNA coronavirus disease 2019 (COVID-19) vaccine (Pfizer-BioNTech, NY, USA). The eye had secondary angle closure glaucoma, bullous retinal detachment, and massive intraocular hemorrhage. Ultrasound showed an ill-defined subretinal mass with moderate internal reflectivity. Magnetic resonance imaging (MRI) confirmed an enhancing heterogeneous subretinal mass. Histopathology showed a necrotic melanocytic lesion arising from the posterior edge of the ciliary body and choroid. Necrotic uveal melanoma was confirmed after expert histopathology opinion. Uveal melanomas can rarely present with tumor necrosis following mRNA COVID-19 vaccination.

Key words: COVID-19 vaccination, necrotic melanoma, spontaneous necrosis, uveal melanoma

Uveal melanoma (UM) is the most common primary intraocular malignancy among Caucasian adults (five to eight per million), but less common among Asians, presenting at least a decade earlier.^[1,2] Spontaneously necrotic UMs are well known, albeit extremely rare (3%–6% of UMs).^[3]

We report an unusual case of necrosis of UM following second dose of BNT162b2 mRNA coronavirus disease 2019 (COVID-19) vaccination (Pfizer-BioNTech, NY, USA) in a middle-aged South Asian male.

Case Report

A 49-year-old Indian male presented with progressive painful severe vision loss in his left eye, 1 day after receiving second dose of BNT162b2 mRNA COVID-19 vaccination (Pfizer-BioNTech).

Access this article online	
Quick Response Code:	Website: www.ijo.in
	DOI: 10.4103/ijo.IJO_3040_21

¹International Eye Cataract Retina Centre, Mount Elizabeth Medical Centre and Farrer Park Medical Centre, ²Department of Ophthalmology and Visual Sciences, Khoo Teck Puat Hospital, ³Departments of Pathology and ⁴Ophthalmology, National University Hospital, National University of Singapore, Singapore

Correspondence to: Dr. Gangadhara Sundar, Department of Ophthalmology, Ophthalmic Oncology Service, National University Hospital, 5 Lower Kent Ridge Road - 119 074, Singapore. E-mail: gangadhara_sundar@nuhs.edu.sg

Received: 05-Dec-2021

Revision: 31-Dec-2021

Accepted: 25-Feb-2022

Published: 28-Apr-2022

He was a heavy smoker and had poorly controlled diabetes mellitus, Bell's palsy, chronic balanitis, and plaque psoriasis. The visual acuity was light perception and intraocular pressure (IOP) was 60 mmHg. The eye had a mid-dilated pupil, microcystic corneal edema, corneal endothelial pigments, shallow anterior chamber, and 2+ anterior chamber cells. A retrolental bullous retinal detachment with an underlying ill-defined temporal subretinal mass was noted [Fig. 1]. The secondary angle closure glaucoma was initially treated with maximal IOP-lowering medications and laser peripheral iridotomy, but he eventually developed a painful blind eye with hyphema and intractable glaucoma.

Ultrasound revealed total retinal detachment, subretinal echoes suggestive of extensive intraocular hemorrhage, and an ill-defined subretinal mass lesion (10.77 mm basal diameter × 13.01 mm height) with moderate internal reflectivity in the temporal aspect of the globe [Fig. 2a and b]. There was no acoustic hollowing or choroidal excavation noted. Magnetic resonance imaging (MRI) orbits showed an enhancing heterogeneous subretinal mass (13 × 11 × 8 mm) superotemporally, which was moderately hyperintense on T1-weighted images and hypointense on T2-weighted images [Fig. 2c and d]. Systemic screening for primary malignancy was negative.

He underwent enucleation with a Medpor® (Stryker, Portage, MI, USA) 22-mm ball implant wrapped in donor sclera. Gross histopathology of enucleated specimen showed large blood clots filling the entire anterior and posterior chambers, total retinal detachment with episcleral congestion, and inflammation [Fig. 3a]. Microscopic examination showed a highly degenerate and necrotic melanocytic lesion at the junction of the ciliary body and choroid [Fig. 3b and c]. At the periphery, few scattered viable human melanoma black (HMB45)-positive and Sry-related HMg-Box gene 10 (SOX10)-positive epithelioid cells with enlarged and irregular nuclei, visible nucleoli, and moderate amount of cytoplasm containing melanin pigment were admixed with a heavy infiltrate of HMB45-negative, SOX10-negative, and CD163-positive melanophages [Fig. 3d]. No scleral extension or optic nerve invasion was noted. After careful deliberation and expert histopathologic opinion, a diagnosis of necrotic choroidal melanoma was confirmed.

Discussion

A variety of ocular adverse events have been reported with the various types of COVID-19 vaccines.^[4] In particular, the BNT162b2 mRNA COVID-19 vaccine (Pfizer-BioNTech) has been associated with Bell's palsy, corneal graft rejections, central serous retinopathy, anterior uveitis, posterior uveitis, panuveitis, and activation of Grave's disease.^[4] To the best

This is an open access journal, and articles are distributed under the terms of the Creative Commons Attribution-NonCommercial-ShareAlike 4.0 License, which allows others to remix, tweak, and build upon the work non-commercially, as long as appropriate credit is given and the new creations are licensed under the identical terms.

For reprints contact: WKHLRPMedknow_reprints@wolterskluwer.com

Cite this article as: Wagle AM, Wu BC, Gopal L, Sundar G. Necrosis of uveal melanoma post-COVID-19 vaccination. Indian J Ophthalmol 2022;70:1837-40.

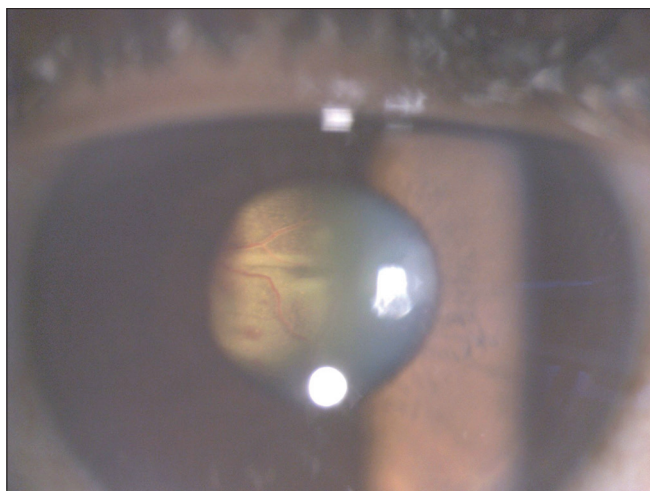


Figure 1: Anterior segment photograph of the left eye showing exudative bullous retinal detachment behind the crystalline lens with an underlying extensive subretinal hemorrhage and an ill-defined mass lesion

of our knowledge, spontaneous necrosis of UM has not been reported following COVID-19 vaccination.

Necrotic UMs are often associated with secondary angle closure glaucoma, hyphema, vitreous hemorrhage, uveal effusion, and inflammation of the uveal, scleral, and episcleral tissues.^[2,3,5,6] Tumor necrosis occurs either as “cellular necrosis” with plasma cell and lymphocyte infiltration along with dispersed free melanin in the tumor and ocular tissues or as “coagulative (ischemic) necrosis” due to a vascular insult.^[5] In the former, a rapidly growing tumor outgrows its blood supply resulting in hypoxia, secondary inflammation, raised IOP, angle closure glaucoma, vascular compromise, and finally, gross ischemia of the ocular contents, while in the latter, vascular occlusion results in release of cytotoxic molecules from dying melanocytes, causing vasculitis and extensive tissue infarction.^[5,6] The close relationship to second dose of COVID-19 vaccination suggests tumor necrosis secondary to vaccine-induced vascular thrombosis in our case, although intravascular thrombi could not be demonstrated. Visible thrombi are rarely seen in long and short posterior ciliary arteries in eyes suspected of having

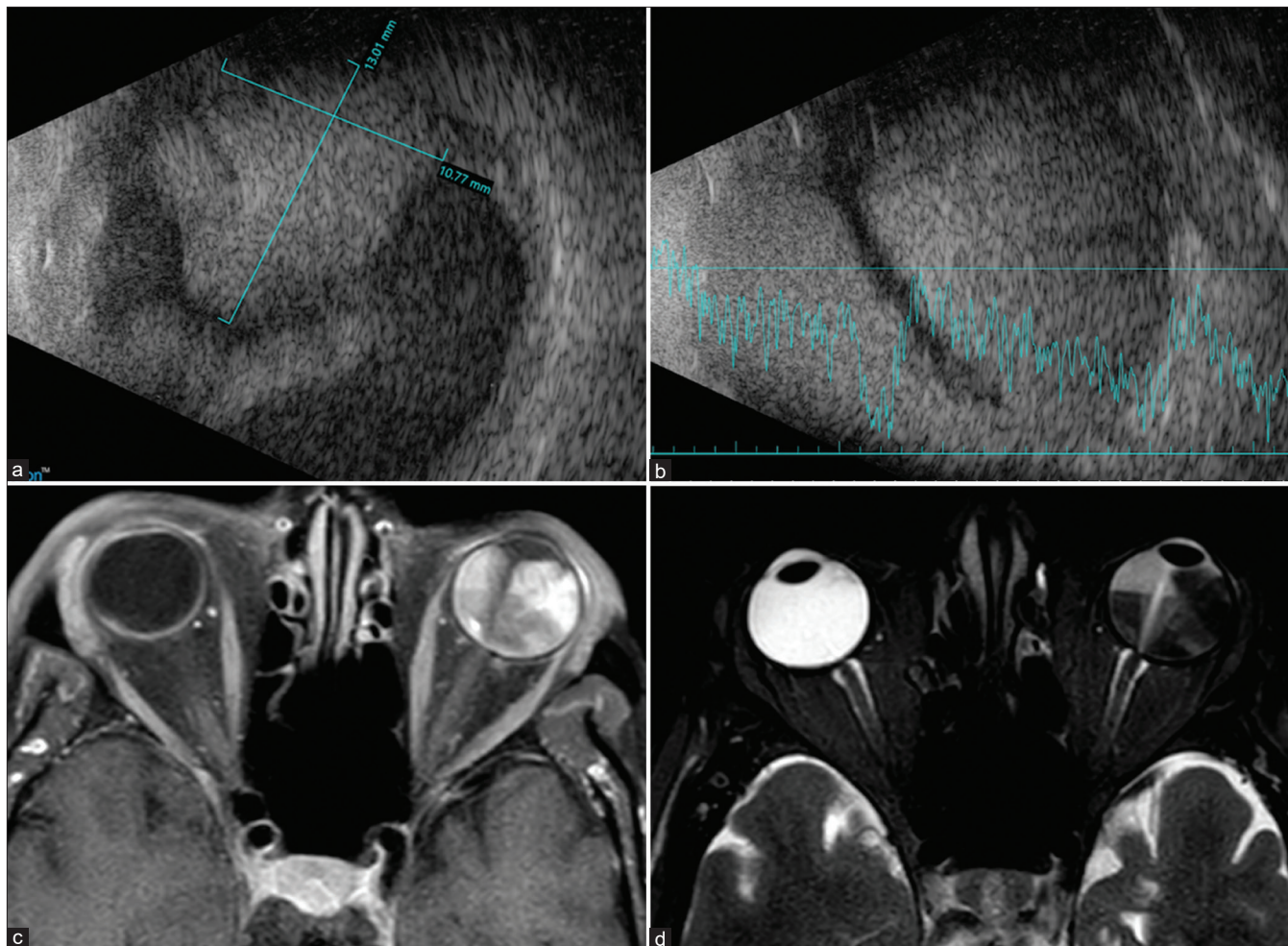


Figure 2: Ocular imaging. (a and b) Ultrasound A and B scans. Total bullous retinal detachment with extensive low to moderate reflectivity, subretinal echoes suggestive of intraocular hemorrhage, and an ill-defined mass lesion having moderate internal reflectivity in temporal aspect of the globe. (c and d) MRI orbit with contrast. Extensive retinal detachment with enhancing heterogeneous subretinal mass in superolateral aspect of left eye, which is moderately hyperintense on T1-weighted images (c) and moderately hypointense on T2-weighted images (d). MRI = magnetic resonance imaging

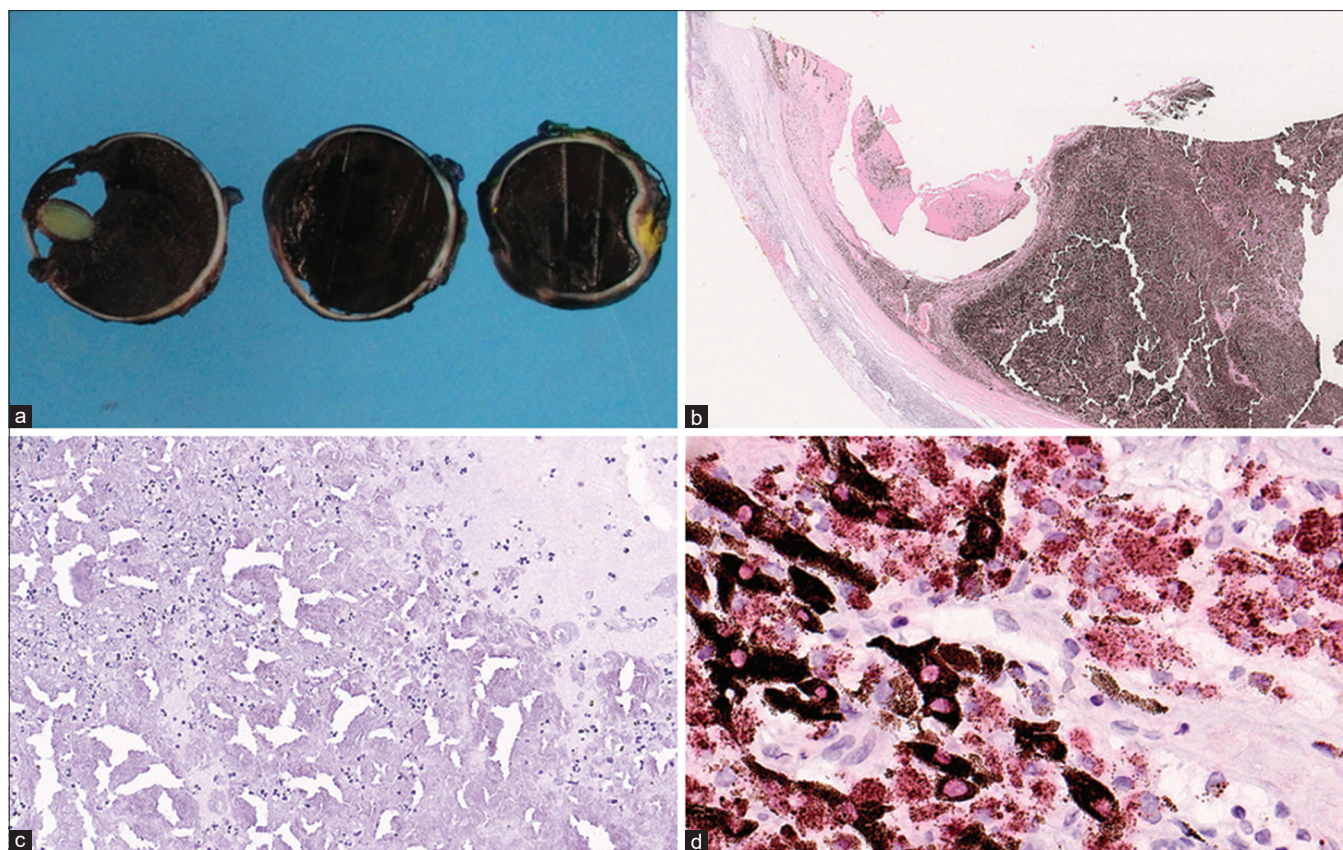


Figure 3: Histopathology. (a) Gross sections show anterior and posterior chambers filled with blood clots and total retinal detachment. (b) Hematoxylin and eosin stain (12.5x). Highly degenerate and necrotic melanocytic lesion, centered at the junction of the posterior edge of the ciliary body and the choroid. (c) Hematoxylin and eosin stain (bleached section, 200x). Extensive necrosis within the melanocytic lesion. (d) SOX10 immunohistochemical stain (400x). Scattered viable SOX10-positive cells with cytoplasmic melanin pigment admixed with abundant SOX10-negative melanophages. SOX10 = Sry-related HMg-Box gene 10

ischemic coagulative necrosis.^[7] However, it is possible that the association we observed is a coincidence as we are unable to establish a definite causal relationship.

COVID-19 vaccination is associated with thrombotic complications; the median age group of onset is 18–48 years, as in our patient.^[8] Although rare, deep vein thrombosis has been reported 48 h after the second dose of mRNA COVID-19 vaccination,^[8] while cerebral venous thrombosis associated with heparin-induced thrombocytopenia (HIT)-like syndrome has been reported with other types of COVID-19 vaccines.^[9] Our patient did not have evidence of thrombocytopenia.

Ultrasound is the preferred diagnostic imaging modality for typical large UMs, with more than 95% accuracy for tumors larger than 3 mm in thickness.^[2,10] The extensive tumor necrosis in our case posed significant challenges for diagnosis because of altered internal tumor reflectivity. Histologically, necrotic melanomas show large areas of tumor necrosis composed of melanoma ghost cells surrounded by melanophages with intact tumor cells limited to the tumor periphery.^[2] In our case, histological diagnosis and subtyping for prognostication were very challenging due to absence of viable tumor cells at the periphery.

Besides clinical features such as large tumor size, ciliary body involvement, and extraocular extension,

gene mutations (chromosome 3 trisomy, disomy 3/6/8, or partial/complete monosomy 3, 6p/6q/8p gain/loss, and BRCA1-associated protein 1 [BAP1]) are predictive of the risk of melanoma-related metastasis.^[1] Unfortunately, owing to the extensive tumor necrosis, useful genetic information was unavailable in our patient. Fortunately, no evidence of metastasis was found and a long-term follow up was advised.

Conclusion

In conclusion, BNT162b2 mRNA COVID-19 vaccination can potentially trigger tumor necrosis from vascular thrombosis. A high index of suspicion is essential for prompt diagnosis, appropriate treatment, and follow-up.

Acknowledgements

The authors would like to sincerely acknowledge the expert histopathology opinion provided by Professor Narsing A. Rao, Keck School of Medicine, University of Southern California, USA for the diagnosis of this case. The authors also acknowledge the assistance provided by Dr. Anurupa A. Wagle for literature search for this manuscript.

Declaration of patient consent

The authors certify that they have obtained all appropriate patient consent forms. In the form the patient(s) has/have given his/her/their consent for his/her/their images and other

clinical information to be reported in the journal. The patients understand that their names and initials will not be published and due efforts will be made to conceal their identity, but anonymity cannot be guaranteed.

Financial support and sponsorship

Nil.

Conflicts of interest

There are no conflicts of interest.

References

1. Wong W, Sundar G, Chee C, Zhao PS, Rajagopalan R, Gopal L. Clinical spectrum, treatment and outcomes of uveal melanoma in a tertiary centre. *Singapore Med J* 2019;60:474-8.
 2. Baumann C, Iannetta D, Coupland SE, Groenewald C, Vishwanath M, Heimann H. spontaneous necrosis of a large choroidal melanoma: Unusual presentation in a 49-year old male. *Ocul Oncol Pathol* 2020;6:174-9.
 3. Damato EM, Damato BE. Detection and time to treatment of uveal melanoma in the United Kingdom: An evaluation of 2,384 patients. *Ophthalmology* 2012;119:1582-9.
 4. Ng XL, Betzler BK, Testi I, Ho SL, Tien M, Ngo WK, *et al.* Ocular adverse events after COVID-19 vaccination. *Ocul Immunol Inflamm* 2021;29:1216-24.
 5. Palamar M, Thangappan A, Shields CL, Ehya H, Shields JA. Necrotic choroidal melanoma with scleritis and choroidal effusion. *Cornea* 2009;28:254-356.
 6. Brannan S, Browne B, Clark BJ. Massive infarction of ocular tissues complicating a necrotic uveal melanoma. *Eye (Lond)* 1998;12:324-5.
 7. Wolter JR. Necrosis of choroidal melanoma in ciliary artery involvement with temporal arteritis. *Br J Ophthalmol* 1989;73:216-9.
 8. Carli G, Nichele I, Ruggeri M, Barra S, Tosetto A. Deep vein thrombosis (DVT) occurring shortly after the second dose of mRNA SARS-CoV-2 vaccine. *Intern Emerg Med* 2021;16:803-4.
 9. Castelli GP, Pognani C, Sozzi C, Franchini M, Vivona L. Cerebral venous sinus thrombosis associated with thrombocytopenia post-vaccination for COVID-19. *Crit Care* 2021;25:137.
 10. Char DH, Stone RD, Irvine AR, Crawford JB, Hilton GF, Lonn LI, *et al.* Diagnostic modalities in choroidal melanoma. *Am J Ophthalmol* 1980;89:223-30.
-