



Since January 2020 Elsevier has created a COVID-19 resource centre with free information in English and Mandarin on the novel coronavirus COVID-19. The COVID-19 resource centre is hosted on Elsevier Connect, the company's public news and information website.

Elsevier hereby grants permission to make all its COVID-19-related research that is available on the COVID-19 resource centre - including this research content - immediately available in PubMed Central and other publicly funded repositories, such as the WHO COVID database with rights for unrestricted research re-use and analyses in any form or by any means with acknowledgement of the original source. These permissions are granted for free by Elsevier for as long as the COVID-19 resource centre remains active.

Clinical Communications: Adult

STEMI Mimic: Focal Myocarditis in an Adolescent Patient After mRNA COVID-19 Vaccine

Michael Azir, MD, Brannon Inman, MD, James Webb, MD, and Lloyd Tannenbaum, MD

Department of Emergency Medicine, San Antonio Uniformed Services Health Education Consortium, Fort Sam Houston, Texas
Reprint Address: Michael Azir, MD, Department of Emergency Medicine, San Antonio Uniformed Services Health Education Consortium,
3551 Roger Brooke Drive, Fort Sam Houston, TX 78234

Abstract—*Background:* In May 2021, the U.S. Food and Drug Administration expanded the Emergency Use Authorization for the Pfizer-BioNTech mRNA Coronavirus disease 2019 (COVID-19) Vaccine (BNT162b2) to include adolescents 12–15 years of age. As vaccine administration continues to increase, potential adverse outcomes, to include myocarditis, are being reported to the Vaccine Adverse Event Reporting System. *Case Report:* This case report describes a 17-year-old male patient who developed focal myocarditis mimicking an ST-segment elevation myocardial infarction (STEMI) 3 days after administration of an mRNA COVID-19 vaccine. *Why Should an Emergency Physician Be Aware of This?* Myocarditis is a rare complication in adolescents receiving mRNA COVID-19 vaccines. Focal myocarditis may demonstrate localizing electrocardiographic changes consistent with a STEMI. Overall, complications of the mRNA COVID-19 vaccines are extremely rare. The vaccine continues to be recommended by public health experts, as the benefits of vaccinations greatly outweigh the rare side effects. Published by Elsevier Inc.

Keywords—myocarditis; mRNA vaccine; BNT162b2; COVID-19; STEMI

Introduction

After a cluster of patients developing pneumonia and viral prodromal symptoms in Wuhan, China, a novel coronavirus, ultimately deemed severe acute respiratory syndrome coronavirus 2 (SARS-CoV-2), was discovered (1,2). After over a year of causing unprecedented death, disease, and economic collapse, the first vaccine in America was given in New York City on December 14, 2020. Initially, this vaccine was only approved for adults ages 18 years and older, however, effective May 2021, the Emergency Use Authorization was amended to allow the BNT162b2 SARS-CoV-2 vaccination to be administered to those between the ages of 12 and 18 years old (3). As of June 27, 2021, over 323,000,000 vaccines have been administered in the United States, with the majority being the mRNA subtype. Adverse outcomes of the mRNA COVID-19 vaccines are rare but do include myocarditis, anaphylaxis, and death (4). Sparse evidence exists regarding the incidence of myocarditis after mRNA vaccination, however, cases are beginning to be reported (5,6). With the exception of the smallpox vaccination, post-vaccination myocarditis is thought to be a relatively rare occurrence (5,7). We present a case of focal myocarditis mimicking an ST-segment elevation myocardial infarction.

Disclaimer: The view(s) expressed herein are those of the author(s) and do not reflect the official policy or position of Brooke Army Medical Center, U.S. Army Institute of Surgical Research, the U.S. Army Medical Department, the U.S. Army Office of the Surgeon General, the Department of the Army, the Department of the Air Force, or the Department of Defense or the U.S. Government.

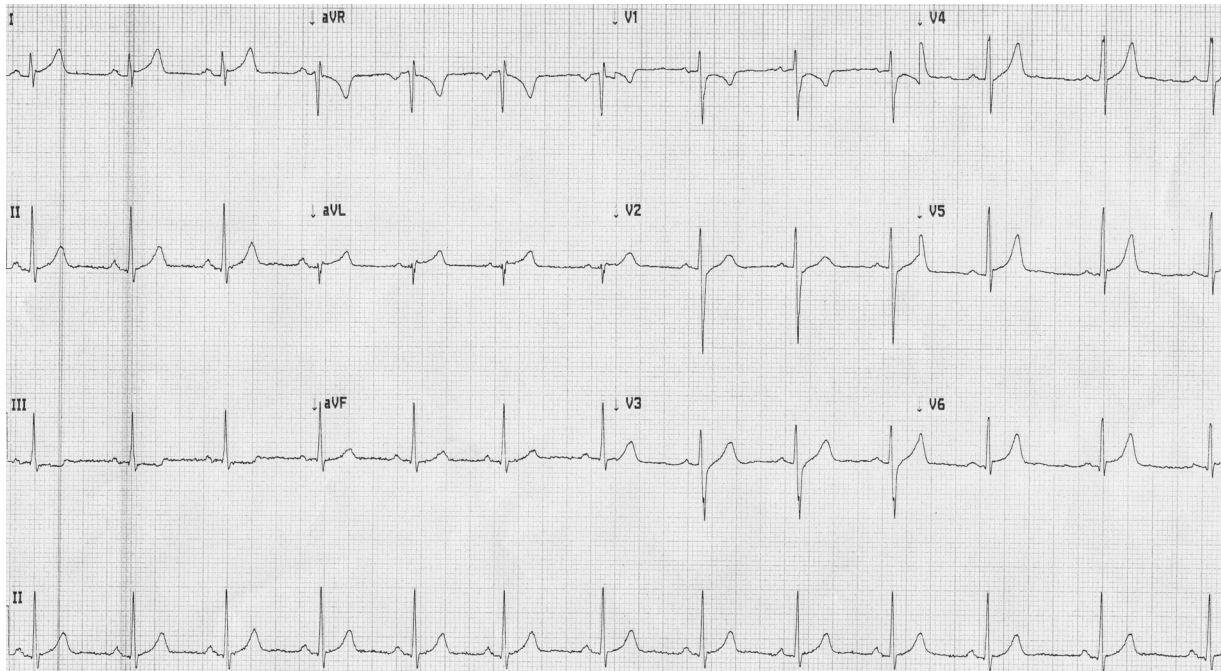


Figure 1. Patient's initial electrocardiogram; sub-1-mm ST-segment elevation in leads I, aVL, V5, V6, and sub-1-mm ST-segment depression in lead III.

tion (STEMI) in a 17-year-old patient after BNT162b2 mRNA SARS-CoV-2 vaccination.

Case Presentation

In June of 2021, a thin, otherwise healthy 17-year-old male presented to the Emergency Department with 3 days of progressively worsening substernal chest pain and exertional dyspnea that began 1 day after his second BNT162b2 vaccination. He had no family history of premature coronary artery disease. Upon presentation, the patient's vitals were within normal limits; blood pressure 119/79 mm Hg, heart rate 90 beats/min, respiration rate 16 breaths/min, and pulse oximetry 97% on room air. His physical examination was benign, including lungs clear to auscultation, no murmurs/rubs/gallops on cardiac examination, and non-reproducible chest pain. The patient's chest x-ray study showed no acute cardiopulmonary abnormalities. The initial electrocardiogram (ECG) showed sub-1-mm lateral ST elevations with sub-1-mm depression in lead III (Figure 1). Bedside ultrasound showed a trace pericardial effusion without wall motion abnormalities. Initial troponin was elevated, at 0.08 ng/mL (normal [nl] < 0.03 ng/mL). Repeat ECG (Figure 2) demonstrated 1-mm elevations in leads I and aVL, with reciprocal depression in lead III. At this time, Cardiology was consulted and a code STEMI was called, given localizing ECG changes meeting STEMI criteria. The patient was given 324 mg of aspirin and sublingual nitroglycerin

without improvement in the patient's chest pain. Intravenous diltiazem was then administered for concerns of possible coronary vasospasm, without improvement in the patient's chest pain or normalization of the patient's ECG. Cardiology elected to obtain a coronary computed tomography angiogram (CCTA), as there was high suspicion for myocarditis and low suspicion for acute coronary syndrome given the patient's age and lack of risk factors. The CCTA showed normal coronary origins with a coronary artery calcium score of 0. Repeat troponin returned at 0.22 ng/mL. The patient was then admitted to the Cardiology service for suspected myocarditis. C-reactive protein was noted to be elevated at 1.9 mg/dL (nl ≤ 0.5 mg/dL), whereas the erythrocyte sedimentation rate was normal at 14 mm/h (nl 0–20 mm/h). Trended troponins continued to rise, with a peak value of 0.39 ng/mL. Cardiac magnetic resonance imaging was performed and showed diffuse, subepicardial delayed gadolinium enhancement of the anterior and lateral wall of the left ventricle, with corresponding heterogeneous T1 signal prolongation and increased short tau inversion recovery signal consistent with a high-risk pattern for myocarditis as depicted in Figure 3; left ventricular ejection fraction was preserved at 55%. The patient was monitored on the Cardiology service for 1 day and was discharged after subsequent troponins downtrended, with plans for close follow-up with the Cardiology Department. The patient followed up in the Pediatric Cardiology clinic 1 month after discharge and endorsed complete resolution of symptoms. No addi-

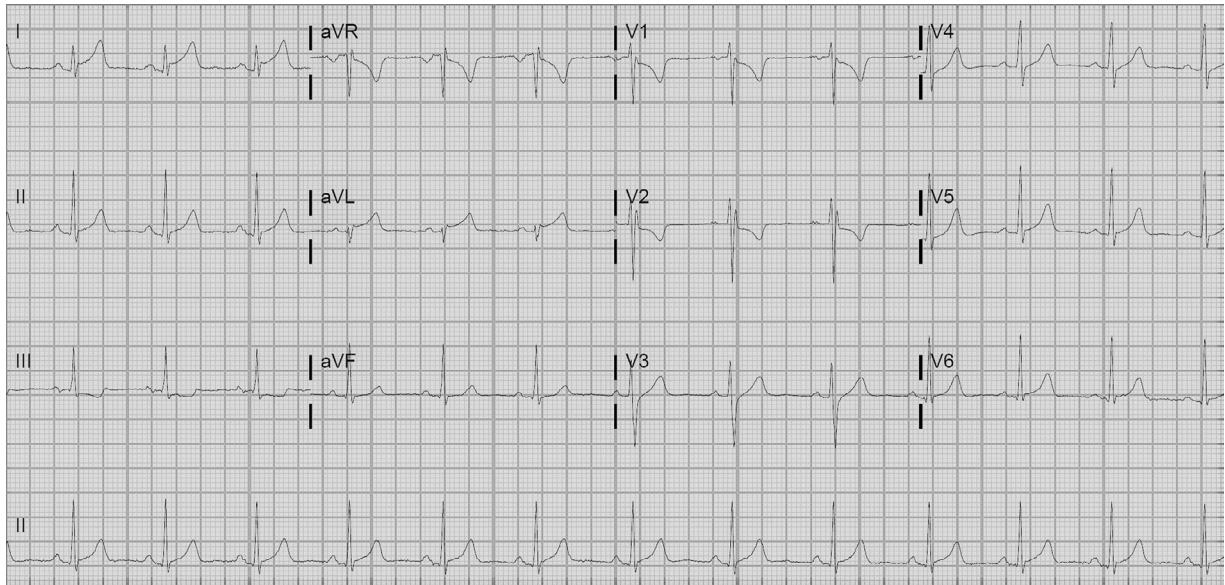


Figure 2. Patient's repeat electrocardiogram; 1-mm ST-segment elevations in leads I and aVL with 1-mm ST-segment depression in lead III concerning for a lateral myocardial infarction.

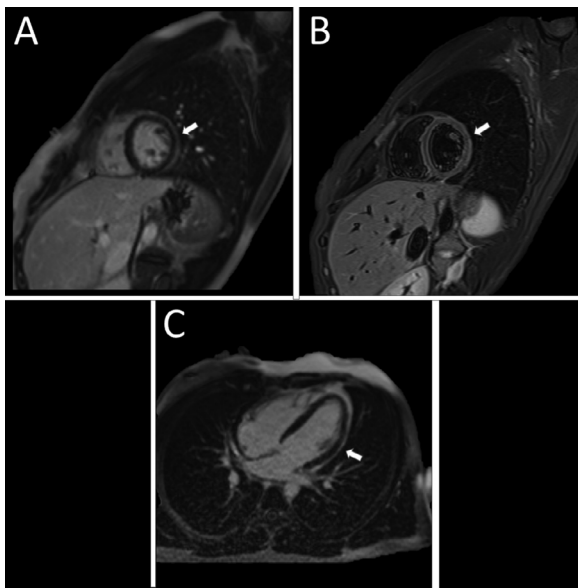


Figure 3. Patient's cardiac magnetic resonance imaging scan; white arrows show subepicardial delayed gadolinium enhancement of the anterior and lateral wall of the left ventricle.

tional laboratory tests or imaging were completed at this time. He was placed on a 6-month activity restriction.

Discussion

Although the BNT162b2 was the first mRNA vaccine approved for Emergency Use Authorization by the U.S. Food and Drug Administration (FDA), the vaccine strat-

egy is not new. In 1990, mRNA was injected into mouse skeletal muscle *in vivo*, resulting in transcription of proteins (8). The mRNA COVID-19 vaccine contains nucleoside-modified messenger RNA that encodes immunogens derived from the spike glycoprotein (S) of SARS-CoV-2 (9). The body's immune response to these immunogens is believed to cause a suspected hypersensitivity myocarditis, although the mechanism is not yet known. Antibody-mediated responses to the spike proteins have also been theorized. New research suggests that elevated levels of anti-spike immunoglobulin G may be linked to more severe systemic infection (10). Biologic agents such as fostamatinib, a therapeutic small-molecule inhibitor of Syk kinase approved by the FDA, are currently being studied to decrease said response (10).

Myocarditis is defined as inflammation of the cardiac myocardium, and it is caused by immune-mediated, toxic, and infectious, most commonly viral, etiologies (11). With the exception of the smallpox vaccination, post-vaccination myocarditis is thought to be a relatively rare occurrence (5,7). Recent reports of myocarditis after novel Emergency Use-Authorized vaccines raise concern for a possible trend of adverse effects (5). According to the Centers for Disease Control and Prevention reports and Vaccine Adverse Event Reporting System (VAERS) data, there were 573 reports of myocarditis and pericarditis after two doses of an mRNA, with a predilection for affecting young adolescent males (data through May 31, 2021) (12). In the 16–39-year age group, a rate of 16.1 per 1 million vaccine doses, or 0.00161%, is reported to VAERS (12). It is unknown what the true rate of myocardial involvement is in SARS-CoV-2 infection, but esti-

mates range from 7–23% (14). Most patients recover with minimal sequelae, though ventricular dysrhythmias are more common in those with healed myocarditis (1,13,14).

Clinical presentations of myocarditis can vary widely, from nonspecific symptoms like chest tightness and shortness of breath to fulminant heart failure. The differential for myocarditis includes acute coronary syndrome, septic myocardial malfunction, and cardiac myopathy (1). Laboratory diagnostic modalities typically include metabolic panel, cardiac troponin T, brain natriuretic peptide, and ECG (1). ECG changes are often diffuse and nonspecific, although focal myocarditis may result in ECG changes that can mimic an acute coronary syndrome, such as in this case (15). For patients with findings concerning for myocarditis, American Heart Association guidelines recommend one or more cardiac imaging modalities, which may include echocardiogram or magnetic resonance imaging (1). Cardiac catheterization is performed at the discretion of the cardiologist, however, some argue there should be a consideration for endomyocardial biopsy at the time of the procedure (1). Management of myocarditis from any cause is largely supportive (1,5,14).

Although reported cases of myocarditis with the mRNA SARS-CoV-2 vaccine exist, the rate of myocardial involvement after vaccination seems to be significantly less than the rate of myocardial involvement from SARS-CoV-2 infection. In light of the greater public health concern surrounding SARS-CoV-2 infection, authorities still recommend vaccination, as it is likely safer than infection from the representative virus (12,13).

Why Should an Emergency Physician Be Aware of This?

As vaccine administration continues to increase, possible adverse outcomes to include myocarditis are becoming more widely recognized. Focal myocarditis may demonstrate localizing ECG changes consistent with a STEMI. The mechanisms of myocardial inflammation, treatment, and long-term complications of suspected COVID-19 mRNA vaccination-related myocarditis are still unclear and require further investigation. At this time, rates of myocardial involvement by SARS-CoV-2 is 7–23%, and rates of myocarditis after vaccination is 0.00161% (12,14). In light of the greater public health concern surrounding SARS-CoV-2 infection, authorities still recommend vaccination, as it is likely safer than infection from the representative virus (12,13).

References

1. Siripanthong B, Nazarian S, Muser D, et al. Recognizing COVID-19-related myocarditis: the possible pathophysiology and proposed guideline for diagnosis and management. *Heart Rhythm* 2020;17:1463–71.
2. Zhu N, Zhang D, Wang W, et al. A novel coronavirus from patients with pneumonia in China, 2019. *N Engl J Med* 2020;382:727–33.
3. FDA.gov. Emergency Use Authorization (EUA) amendment for an unapproved product review memorandum identifying information application type EUA (event-driven EUA request) amendment application number EUA 27034 (Amendment 132) sponsor Pfizer, Inc., on behalf of BioNTech SE submission. 2021. Available at: <https://www.fda.gov/media/148542/download>. Accessed July 14, 2021.
4. Centers for Disease Control and Prevention (CDC). Selected adverse events reported after COVID-19 vaccination. Available at: <https://www.cdc.gov/coronavirus/2019-ncov/vaccines/safety/adverse-events.html#:~:text=Anaphylaxis%20after%20COVID%2D19%20vaccination,and%20immediately%20treat%20the%20reaction>. Accessed July 14, 2021.
5. Abu Mouch S, Roguin A, Hellou E, et al. Myocarditis following COVID-19 mRNA vaccination. *Vaccine* 2021;39:3790–3.
6. Montgomery J, Ryan M, Engler R, et al. Myocarditis following immunization with mRNA COVID-19 vaccines in members of the US Military. *JAMA Cardiol* 2021;6:1202–6.
7. Cassimatis DC, Atwood JE, Engler RM, Linz PE, Grabenstein JD, Vernalis MN. Smallpox vaccination and myopericarditis: a clinical review. *J Am Coll Cardiol* 2004;43:1503–10.
8. Wolff JA, Malone RW, Williams P, et al. Direct gene transfer into mouse muscle in vivo. *Science* 1990;247:1465–8.
9. Vogel AB, Kanevsky I, Che Y, et al. Bnt162b vaccines protect rhesus macaques from sars-cov-2. *Nature* 2021;592:283–9. Available at: <https://www.nature.com/articles/s41586-021-03275-y>.
10. Hoepel W, Chen HJ, Geyer CE, et al. High titers and low fucosylation of early human anti-SARS-CoV-2 IgG promote inflammation by alveolar macrophages. *Sci Transl Med* 2021;13:eabf8654.
11. Caforio AL, Pankuweit S, Arbustini E, et al. Current state of knowledge on aetiology, diagnosis, management, and therapy of myocarditis: a position statement of the European Society of Cardiology Working Group on Myocardial and Pericardial Diseases. *Eur Heart J* 2013;34:2636–48 2648a–d.
12. Shimabukuro T. COVID-19 vaccine safety updates. Vaccines and Related Biological Products Advisory Committee. Meeting presentation, June 10, 2021. Available at: <https://www.fda.gov/media/150054/download>. Accessed October 12, 2021.
13. Amanat F, Krammer F. SARS-CoV-2 vaccines: status report. *Immunity* 2020;52:583–9.
14. Pirzada A, Mokhtar AT, Moeller AD. COVID-19 and myocarditis: what do we know so far? *CJC Open* 2020;2:278–85.
15. Dec Jr GW, Waldman H, Southern J, Fallon JT, Hutter Jr AM, Palacios I. Viral myocarditis mimicking acute myocardial infarction. *J Am Coll Cardiol* 1992;20:85–9.