



Palmoplantar lichenoid drug eruption following the administration of Pfizer-BioNTech COVID-19 vaccine

Giovanni Paolino, MD, PhD,^{a,b} and Franco Rongioletti, MD^b
Milan, Italy

Key words: COVID-19; lichen; lichenoid drug eruption; SARS-CoV-2; vaccine.

INTRODUCTION

There are some reports of new-onset or worsening of lichen planus (LP) as a cutaneous manifestation of COVID-19 vaccination,^{1,2} although infrequent. However, LP involving the palms and soles is uncommon and usually does not have typical morphologic features; thus, it is often misdiagnosed. Various investigators have described different morphologic patterns of palmoplantar LP in anecdotal cases or short series such as erythematous and desquamative plaques, punctate keratosis, diffuse hyperkeratosis, vesicular or ulcerated lesions, umbilicated papules, and diffuse hyperpigmentation of the palms and/or soles.³ Lichenoid drug eruption (LDE) is a rare type of cutaneous lichenoid manifestation induced by several drugs; from a clinical and histopathologic point of view, LDE resembles LP and, therefore, it is sometimes difficult to differentiate one from the other.⁴⁻⁶ As in LP, the involvement of the palms and soles is very rare in LDE, with only sporadic cases reported in the literature.^{7,8} Both LP and LDE sometimes may occur after vaccination, especially after hepatitis B and influenza vaccinations.⁶ Herein, we report a case of a new-onset LDE triggered by the Pfizer-BioNTech COVID-19 vaccine involving only the palms and soles.

CASE REPORT

A 63-year-old woman, without any personal history of LP, was seen for pruritic and disabling acral lesions that had appeared 72 hours after the second dose of the Pfizer-BioNTech COVID-19

Abbreviations used:

LDE: lichenoid drug eruption
LP: lichen planus

vaccine. She reported minimal skin lesions on her palms after the first dose that healed spontaneously. On examination, there were hyperkeratotic papules and plaques with scale on an erythematous background, involving both her palms and spreading to the wrists (Fig 1, A). The soles showed diffuse, thick hyperkeratosis with fissures extending on the lateral borders (Fig 1, B), causing pain and discomfort while walking. She did not have any additional skin involvement or mucosal, hair, or nail lesions. The patient had been taking enalapril for 2 years for arterial hypertension. Dermatoscopic examination of the palmar lesions revealed large scales over a white-to-reddish background, sparse whitish scales, and striae. A skin biopsy was performed, which showed orthohyperkeratosis with focal parakeratosis, hypergranulosis with interruption of the granular layer, irregular epidermal hyperplasia, vacuolar degeneration of the basal layer, and a moderately dense lichenoid lymphocytic infiltrate (Fig 2, A) with apoptotic keratinocytes and scattered eosinophils in the dermis (Fig 2, B). In view of the clinical and pathologic correlation and the timing of the skin eruption with respect to the vaccine, LDE triggered by the COVID-19 vaccine was diagnosed. The patient was administered 25 mg/d of acitretin and

From the Unità di Dermatologia Istituto di Ricovero e Cura a Carattere Scientifico (IRCCS) Ospedale San Raffaele, Milan^a; and Dermatologia Clinica Università Vita-Salute San Raffaele, Milan.^b

Funding sources: None.

IRB approval status: Not applicable.

All patient photographs and medical information were provided by the authors at the time of submission of this article to the journal stating that the patient gave consent for their photographs and medical information to be published in print and online, with the understanding that this information may be publicly available.

Correspondence to: Giovanni Paolino, MD, PhD, Istituto di Ricovero e Cura a Carattere Scientifico (IRCCS) Ospedale San Raffaele, Via Olgettina 60, 20132, Milano, Italy. E-mail: paolino.giovanni@hsr.it.

JAAD Case Reports 2022;21:182-4.

2352-5126

© 2022 by the American Academy of Dermatology, Inc. Published by Elsevier, Inc. This is an open access article under the CC BY-NC-ND license (<http://creativecommons.org/licenses/by-nc-nd/4.0/>).

<https://doi.org/10.1016/j.jidcr.2022.01.014>

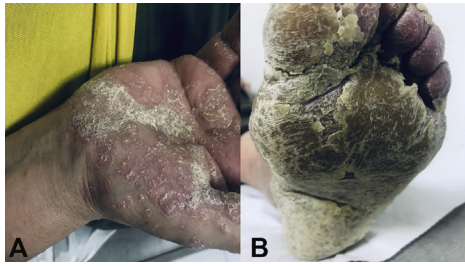

Fig 1. **A**, Hyperkeratotic papules and plaques with scales on erythematous background on both palms spreading to the wrists. **B**, The soles showed diffuse, thick, psoriasiform hyperkeratosis with fissures extending on the lateral borders.

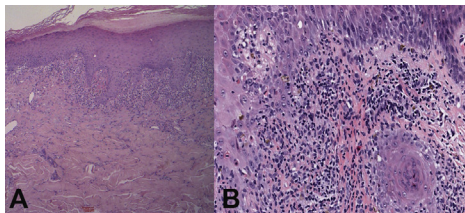


Fig 2. **A**, Histology showed orthohyperkeratosis with focal parakeratosis, hypergranulosis, irregular epidermal hyperplasia, vacuolar degeneration of the basal layer, apoptotic keratinocytes, and a moderately dense lichenoid lymphocytic infiltrate. **B**, Scattered eosinophils were present in the inflammatory infiltrate in the dermis. (**A** and **B**, Hematoxylin-eosin stain; original magnifications: **A**, $\times 10$; **B**, $\times 50$.)

topical calcipotriene/betamethasone dipropionate foam. One month later, there was total clearing of the acral lesions with residual hyperpigmentation of the palms (Fig 3, *A* and *B*). The patient discontinued acitretin after 2 months, and she remained free of lesions at the 5-month follow-up.

DISCUSSION

Although LDE shows clinical and pathologic features similar to LP, its clinical presentation is sometimes more scaly, eczematous, and/or psoriasiform, resolving with greater residual hyperpigmentation, while histopathology may exhibit focal parakeratosis with interruption of the granular layer, a higher number of apoptotic keratinocytes, and eosinophils within inflammatory cells.⁷ In our case, the clinical and histologic features were consistent with a diagnosis of LDE. Moreover, the development of a rare and atypical presentation of LDE, the temporal relationship, and the presence of eosinophils on skin biopsy are indicative of a pathogenic role of the COVID-19 vaccine in triggering the skin reaction, although skin tests were not performed. The validity of epicutaneous and intradermal testing to the Pfizer-BioNTech COVID-19 vaccines, however, has not yet been established.⁹

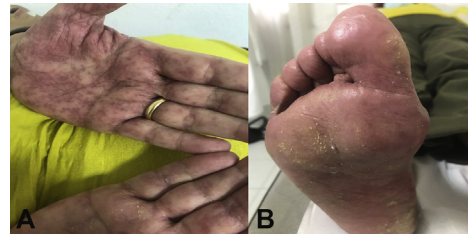

Fig 3. **A**, Complete clearing of the palmar lesions with residual hyperpigmentation after 1 month of therapy with acitretin. **B**, Clearing of the hyperkeratotic lesions of the soles with minimal residual xerosis after 1 month of therapy with acitretin.

There is growing evidence that not only the COVID-19, but also the relative vaccines anti COVID-19 can cause a variety of skin reactions. In this setting, type I hypersensitivity reactions (eg, urticaria, angioedema, and anaphylaxis) and type IV hypersensitivity reactions (eg, inflammatory reactions in the injection site, morbilliform and erythema multiforme-like rashes) are the ones more commonly observed.¹⁰ Generally, the key initiating event that leads to the development of postimmunization LDE is not well understood. LDE (as well as LP) is characterized by persistently activated CD8⁺ cytotoxic T lymphocytes against epidermal cells⁶; the lymphocytes can induce apoptosis of basal keratinocytes, generating various cytokines (eg, interferon gamma, interleukin 2) in order to enhance the expression of class II major histocompatibility complex molecules and antigen presentation to CD4⁺ T cells.⁶ Specifically, COVID-19 vaccines elicit a helper T cell type 1 response, increasing the serum levels of the abovementioned cytokines and inducing a lichenoid eruption, by a mechanism of molecular mimicry caused by genetic similarities of SARS-CoV-2 spike protein components to endogenous cross-reactive human antigens.¹⁰

Topical steroids are the first-line treatment for both LP and LDE, in addition to the suspension of the causative drug for LDE. For patients in whom corticosteroid treatment has failed, who relapse after corticosteroid therapy, or who have contraindications to corticosteroids, acitretin may be considered a potential second-line therapy. In our patient, acitretin was chosen as the first-line therapy, given the hyperkeratotic aspect of the lesions on the palms and soles. Acitretin treatment resulted in a rapid response, with residual hyperpigmentation on the palms, confirming acitretin as a valid and alternative first-line treatment for LP and LDE.

In conclusion, we report a rare presentation of an LDE following the administration of Pfizer-BioNTech COVID-19 vaccine. Dermatologists play a pivotal

role in recognizing even rare clinical manifestations induced by the new anti-SARS-CoV-2 vaccines, with the aim of making rapid diagnoses, starting a quick and prompt treatment, and not discouraging the population from using the anti-SARS-CoV-2 vaccines, which currently maintain a good general safety profile.

Conflicts of interest

None disclosed.

REFERENCES

- Hiltun I, Sarriugarte J, Martínez-de-Esproncada I, et al. Lichen planus arising after COVID-19 vaccination. *J Eur Acad Dermatol Venereol*. 2021;35(7):e414-e415. <https://doi.org/10.1111/jdv.17221>
- Merhy R, Sarkis AS, Kaikati J, El Khoury L, Ghosn S, Stephan F. New-onset cutaneous lichen planus triggered by COVID-19 vaccination. *J Eur Acad Dermatol Venereol*. 2021;35(11):e729-e730. <https://doi.org/10.1111/jdv.17504>
- Sánchez-Pérez J, Rios Buceta L, Fraga J, García-Díez A. Lichen planus with lesions on the palms and/or soles: prevalence and clinicopathological study of 36 patients. *Br J Dermatol*. 2000;142(2):310-314. <https://doi.org/10.1046/j.1365-2133.2000.03303.x>
- Ziraldó M, Theate I, Vanhootehem O. Drug-induced lichenoid exanthema by a vaccine against COVID-19 (Vaxzevria). *Dermatol Reports*. 2021;13(3):9358. <https://doi.org/10.4081/dr.2021.9358>
- Lai YC, Yew YW. Lichen planus and lichenoid drug eruption after vaccination. *Cutis*. 2017;100(6):E6-E20.
- Correia C, Fernandes S, Soares-de-Almeida L, Filipe P. Exuberant lichenoid eruption after Oxford-AstraZeneca COVID-19 vaccine: a singular case. *J Eur Acad Dermatol Venereol*. Published online December 16, 2021. <https://doi.org/10.1111/jdv.17872>
- Kolm I, Eggmann N, Kamarashev J, Kerl K, French LE, Hofbauer GF. Lichenoid drug eruption following intravenous application of orally formulated diamorphine, a semisynthetic heroin. *Case Rep Dermatol*. 2013;5(2):176-180. <https://doi.org/10.1159/000353305>
- Swartz JS, Budev M, Mehta A. A case study of a lichenoid drug eruption due to oral cyclosporine. *J Allergy Clin Immunol*. 2007;119(1):S270. <https://doi.org/10.1016/j.jaci.2006.12.427>
- Vander Leek TK, Chan ES, Connors L, et al. COVID-19 vaccine testing and administration guidance for allergists/immunologists from the Canadian Society of Allergy and Clinical Immunology (CSACI). *Allergy Asthma Clin Immunol*. 2021;17(1):29. <https://doi.org/10.1186/s13223-021-00529-2>
- Gambichler T, Boms S, Susok L, et al. Cutaneous findings following COVID-19 vaccination: review of world literature and own experience. *J Eur Acad Dermatol Venereol*. 2022;36(2):172-180. <https://doi.org/10.1111/jdv.17744>